



IMPROVEMENT OF TACTICAL APPROACHES IN THE TREATMENT OF DESTRUCTIVE FORMS OF ACUTE PANCREATITIS

Murod Sh.Khakimov

Doctor of Medical Sciences, Professor, Head of the Department of Faculty and Hospital Surgery No. 1,
murad_72@mail.ru;

Maxmud R.Karimov

Candidate of Medical Sciences, Associate Professor of the Department of Faculty and Hospital Surgery No. 1,
referenttma@gmail.com;

Bekzad B. Fayzullaev

Candidate of the Department of Faculty and Hospital Surgery No. 1.

Azizbek F.Valijonov

5th year student of the medical faculty of the Tashkent Medical Academy. Tashkent, Uzbekistan,

AzizbekValijonov97@gmail.com;

Shirina A. Valijonova

5th year student of the medical faculty of the Tashkent Medical Academy. Tashkent, Uzbekistan, misirova-1998@mail.ru;

Article history:	Abstract:
Received: June 28 th 2022 Accepted: July 28 th 2022 Published: September 4 th 2022	Despite the rapid development of medical science and technology, the issues of diagnosis and treatment of destructive forms of acute pancreatitis remain one of the complex problems of modern urgent surgery. The frequency of this disease increases from year to year, and in the structure of abdominal urgent surgery, this pathology occupies a leading place, and in terms of growth rates, it is ahead of all other emergency abdominal diseases. It should be noted that along with the increase in the absolute number of patients, there is an even greater tendency to the growth of destructive forms. In Uzbekistan, according to the Institute of Health and Medical Statistics, more than 600 operations for pancreatic necrosis are performed annually in the country. At the same time, postoperative mortality in some regions reaches 28.6-30.8%.

Keywords: destruction, sequestration, pancreatic necrosis, pancreatitis, monitoring

OBJECTIVE: To determine the timing of the sequestration phase based on multispiral computed tomography and morphological studies.

MATERIALS AND METHODS: The following methods were used to achieve the research goal and solve the tasks set: general clinical, radiation, morphological and statistical research methods.

RESULTS AND DISCUSSION: We analyzed the data of 68 tomograms of patients in the control group in the dynamics of treatment. To assess the nature of changes in MSCT, we determined the frequency of the most frequent signs of pancreatic necrosis. On the 7th day, 32 patients were examined, on the 14th - 12, on the 20th - 10, on the 30th - 7, on the 45th - 5 and on the 60th day - 2 patients.

Table 1
Frequency of tomographic signs of pancreatic necrosis

Day	7	14	20	30	45	60
Number of studies	32	12	10	7	5	2
MSCT signs	Frequency of occurrence of signs					
Diffuse increase in the size of the pancreas	32 (69,5%)	12 (32,4%)	10 (23,8%)	7 (20,58%)	5 (17,2%)	2 (9,5%)
Smoothness of the contours of the pancreas	32 (69,5%)	12 (32,4%)	12 (28,5%)	18 (52,9%)	7 (24,1%)	4 (19,0%)
Expansion of the Virsung duct	5 (10,8%)	3 (8,1%)	1 (2,4%)	0	0	0

Heterogeneity of the pancreatic parenchyma	23 (50%)	15 (40,5%)	8 (19,0%)	5 (14,6%)	3 (10,3%)	1 (4,76%)
Compaction of parapancreatic fiber	11 (23,9%)	9 (24,3%)	13 (30,9%)	8 (23,8%)	5 (17,2%)	1 (4,76%)
The presence of free fluid in bursa omentalis	9 (19,5%)	5 (13,5%)	3 (7,15%)	0	0	0
Abdominal effusion	7 (15,2%)	6 (16,2%)	4 (9,52%)	2 (5,9%)	2 (6,8%)	0
Effusion in the pleural cavity	7 (15,2%)	4 (10,8%)	1 (2,3%)	1 (2,9%)	1 (3,4%)	0
The presence of sequestered tissues	0	0	0	2 (5,9%)	6 (20,7%)	9 (42,8%)

On the 7th day after the disease, when analyzing the MSCT data, a diffuse increase in the size of the pancreas was diagnosed in 100% of observations. Signs such as smoothness of contours, compaction of parapancreatic fiber, heterogeneity of parenchyma, which are absolute

signs of a destructive process in the pancreas, were found in more than 90% of cases. The densitometric density of the pancreas on the Hounsfield scale was 30-35 HU

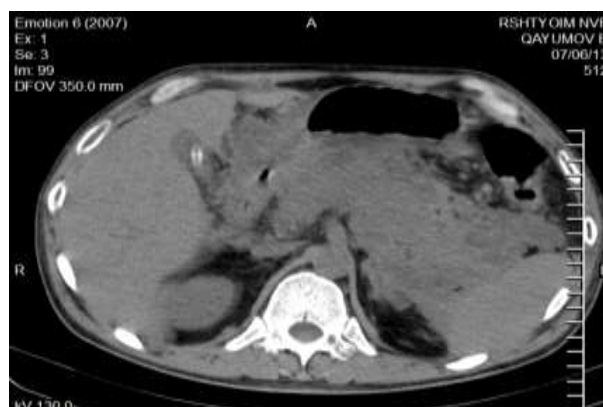

Fig 1: MSCT picture at the SP(sterile pancreatic necrosis) on the 7th day.

On the 14th day of MSCT, the picture of the pancreas and the parapancreatic zone did not change much. Diffuse magnification, smoothness of contours, heterogeneity of parenchyma were preserved in 100% of observations. Intravenous contrast revealed hypo- and avascular foci that spread to one or two anatomical areas involving parapancreatic fiber or even the entire pancreas.. The expansion of the virusung duct did not

exceed 15% of cases. At the same time, this indicator coincided with the ultrasound data. According to Filin V.I., on the 14th day the disease enters the sequestration phase. However, in our observations, no foci of sequestration were detected in any case during these periods. The densitometric density of the pancreas remained at the figures 30-35 HU.

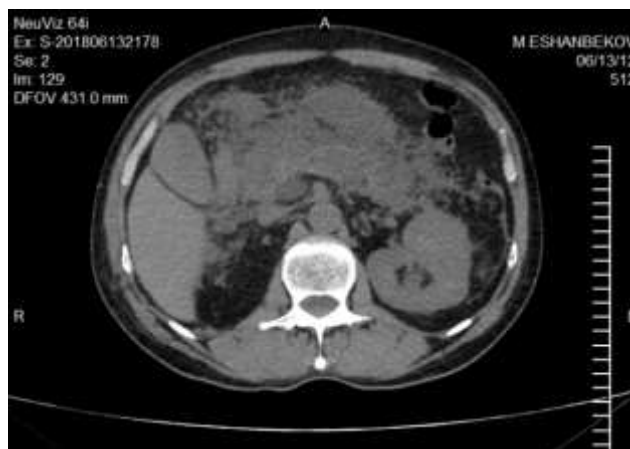


Fig. 2. MSCT picture at the SP on the 14th day.

On the 20th day, most patients retain diffuse enlargement of the gland, smoothness of contours, heterogeneity of parenchyma. The pathological process extends to the parapancreatic fiber, heterogeneous infiltrates without clear boundaries are determined in the retroperitoneal space. The frequency of occurrence of free fluid in the omentum, abdominal and pleural cavities is significantly reduced. In almost all cases, the

diameter of the virsung duct is normalized. Sequestration foci are not determined in any observation in the pancreatic parenchyma and retroperitoneal space. The density of the gland is reduced to 25-30 HU. With intravenous contrast, there is the presence of poorly defined hypodensive areas of necrosis in the form of zones of absence or insufficient accumulation of contrast preparation.

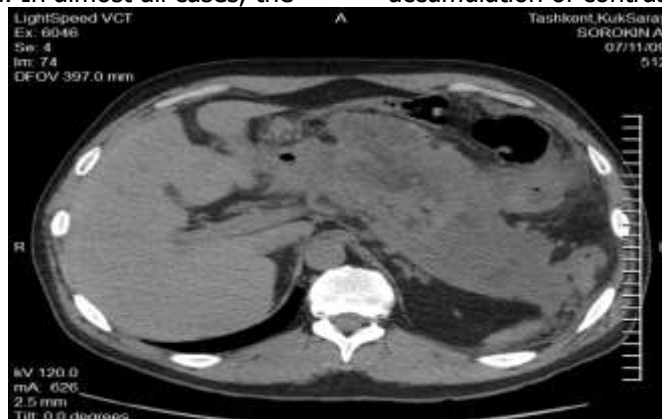


Fig.3. MSCT picture at the SP on the 20th day.

On the 30th day, the process of organizing necrosis in the pancreatic parenchyma contributes to the formation of pseudocysts containing necrotic tissues, single sequestration sites are formed. However, these changes were noted only in 4 (11.8%) patients. On tomograms, the sequestration sites are visualized as structureless alternating zones with low and high density according

to the type of "black dots", which do not increase with intravenous contrast. Almost 70% of patients retain heterogeneity of the pancreatic parenchyma, diffuse enlargement of the gland with smoothness of its contours. The density of the gland ranges from 25-30 HU.

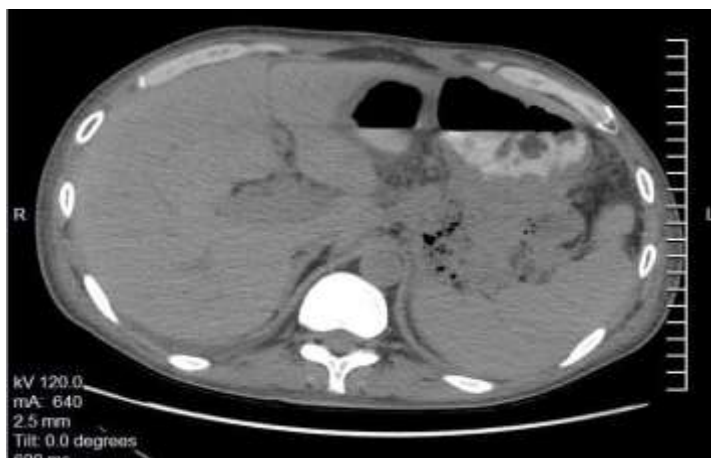


Fig. 4. MSCT picture at the SP on the 30th day.

On the following day (45-60 days), the tomographic signs of diffuse lesions of the pancreatic tissues and parapancreatic fiber decrease. Heterogeneity of the parenchyma, smoothness of the contours of the gland, a diffuse increase in its size is noted in less than 50% of patients, clearer contours of the pancreas and lesion zones appear in the parapancreatic tissue. During these periods, the inflammatory process is limited, the frequency of occurrence of free fluid in the pleural and

abdominal cavities does not exceed 10%. The foci of sequestration are increasing in volume. The densitometric density of the pancreatic parenchyma is 25-30 HU, whereas in the sequestration zone the tissue density ranges from 5 to 15 HU. With intravenous contrast, heterogeneity of the accumulation of contrast agent is noted, which is the fact of the presence of the sequestration process in the tissues of the pancreas

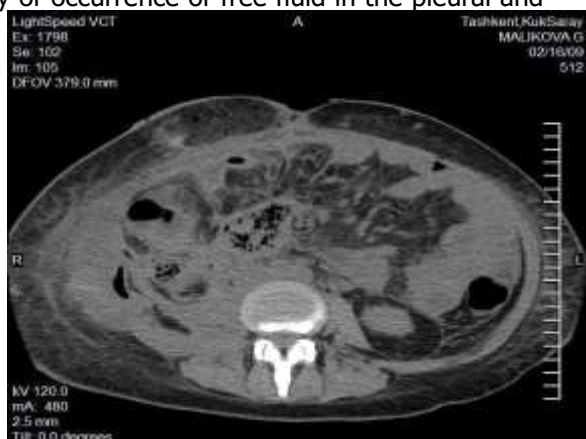

Fig. 5. MSCT picture at the SP on the 45th day.

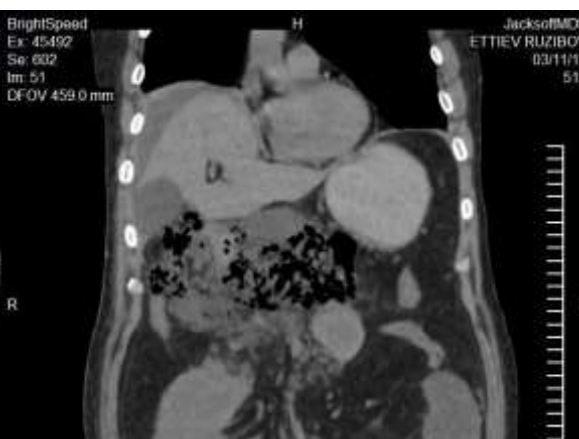


Fig.6. MSCT picture at the SP on the 60th day.

CONCLUSION: Our research shows that contrary to the classical data of Filin V.I., according to which the phase of sequestration begins from the 14th day, this process begins rather later. This fact is a fundamental point in choosing a treatment method for SP (sterile pancreatic necrosis), since with the ineffectiveness of conservative therapy, surgical treatment is advisable to be carried out precisely in the sequestration phase. Examination and dynamic observation of patients with pancreatic necrosis using radiation diagnostics methods allowed us to specify the timing of surgical treatment. Without focusing on all the positive aspects of the use

of MSCT in the treatment of acute destructive pancreatitis, it should be noted that a clear visualization of structural changes and determination of the sequestration phase helps to avoid unnecessary surgical interventions and cure patients with conservative methods.

Thus, morphological studies conducted in infected pancreatic necrosis allowed us to distinguish two clinical forms – infiltrative and sequestered form. The importance of the conducted studies and the data obtained lies in the fact that, depending on the clinical



form of infected pancreatic necrosis, the basic principle of treatment is determined.

REFERENCES:

1. Александрова Н.П., Фирсов Н.Н. Вязкость крови как фактор риска развития декомпенсации кровообращения у хирургических больных. // Ж. Тромбоз, гемостаз и реология. - 2015. - № 1. - С. 28-33.
2. Алексеев С.А., Антиперович О.Ф., Алексеев В.С., Алексеев Д.С. Морфоструктурные нарушения внутренних органов, обуславливающие развитие полиорганной недостаточности при остром некротизирующем панкреатите // Ж. Научный взгляд в будущее. - 2018. - Т 3. - . № 11. - С. 123-126.
3. Ахмедов, Ш.Х., Шоназаров И.Ш. Значение раннего энтерального питания у больных с синдромом интраабдоминальной гипертензии при тяжелом остром панкреатите // Ж. Инновационное развитие: потенциал науки и современного образования. - 2020. - С. 274-276.
4. Бельских Л.В., Василенко И.А., Ватазин А.В. Real-time визуализация тромбоцитов методом компьютерной лазерной фазометрии в оценке нарушений тромбоцитарно-коагуляционного потенциала при панкреонекрозе // Ж. Глобальный научный потенциал. - 2015. -№ 8. - 46-50.
5. Белякин С.А., Луганская Ю.А., Апевалов С.И., Рыжман Н.Н., Азбаров А.А., Хлобыстов В.А., Григорьев К.Б. Эффективность консервативной терапии в сочетании с продленной вено-венозной гемофильтрацией при лечении стерильных форм острого панкреатита // Ж. Вестник Российской военно-медицинской академии. - 2013. -№ 1. - 64-68.
6. Бережной С.Г. Лукач В.Н., Цыганков П.В. Оценка показателей кислородного статуса у пациентов в критических состояниях с системной воспалительной реакцией // Анестезиология и реаниматология. - 2013. - № 3. - С. 35-40.
7. Каримов Ш.И., Ким В.Л., Хакимов М.Ш., Каримов М.Р. Клиническая система оценки тяжести острого панкреатита // Медицинский журнал Узбекистана. - 2005. - № 1. - С. 68-70.
8. Каримов Ш.И., Ким В.Л., Хакимов М.Ш. Современные проблемы диагностики острого панкреатита и разработка клинической системы его диагностики // Ж. Медицинский журнал Узбекистана.- 2005. - № 2 - С. 14-18.
9. Каримов Ш.И., Ким В.Л., Хакимов М.Ш. Малоинвазивные вмешательства в хирургии острого панкреатита // Журнал теоретической и клинической медицины. - 2005. - № 4. - С. 31-37.
10. Карпов Щ.Э., Ветшев П.С., Стойко Ю.М., Маады А.С., Алексеев К.И., Левчук А.Л. Место панкреатического стентирования в профилактике и лечении острого панкреатита после эндоскопических вмешательств на БДС // Ж. Вестник Национального медико-хирургического центра им. Н.И. Пирогова. - 2014. - №3. - с. 20 - 23.