



EXPRESSION LEVEL OF KI-67, P 53 AND TTF MARKERS IN VARIOUS FORMS OF THYROID CANCER

Abdirazakov I.A.Tursunov Kh.Z.

Tashkent Medical Academy

Article history:

Received: November 20th 2022
Accepted: December 20th 2022
Published: January 30th 2023

Abstract:

The results obtained by modern immunohistochemical methods of thyroid gland malignancy are important for determining the level of malignancy of the tumor, target therapy against the immunoactive bodies of the cells in its components, or indicators of active development of secondary changes in the tumor. By studying the results obtained in this research work, it will be the basis for pre-planning and development of treatment tactics. At the same time, it consists in studying the dynamic changes of the tumor and the level of expression of immunomarkers through immunohistochemical examination.

Keywords: immunohistochemical examination, thyroid tumor, carcinoma, follicular tumor, expression, proliferation.

RELEVANCE OF THE TOPIC. The new edition of the WHO Classification of Endocrine Tumors is based on the decision of MAIR v Lyon, France, 26-28 April 2016, by an international expert working group of 166. The publication of a new edition of the classifications is based on the scientific achievements of recent years and is confirmed by the specificity of immunohistochemical indicators of carcinogenesis of thyroid tumors.

Based on this classification, the following forms of malignant thyroid tumors are distinguished: papillary, follicular, medullary (oncocytic) and poorly differentiated anaplastic carcinomas.

PURPOSE: to study specific immunoexpression features in immunohistochemical examinations of malignant tumors of the thyroid gland.

MATERIALS AND METHODS: 683 tumors of the Thyroid gland were surgically removed during 10 years in the practice of the Republican Specialized Oncology and Radiology Scientific and Practical Medical Center and branch of the Tashkent region.

RESEARCH RESULTS AND THEIR DISCUSSION: Ki-67 is a marker of cell proliferation and is expressed at different levels in all cell activation phases, i.e. G1, S, G2, M. From the initial phase of cell activation, G1 to M phase, this marker increases and reaches a maximum by the metaphase of mitosis. In the early G1 phase, the Ki-67 marker is located at the centromere of the satellite DNA and at the telomere of the chromosome. In the middle phases of cell activation, the Ki-67 marker appears in the nucleus, and by the G2 phase, it is expressed both in the nucleus and in the karyoplasm. When the cell enters post-mitotic G0, the Ki-67 marker is degraded by proteosomes,

undergoes complete catabolism, and is not expressed in interphase cells. Therefore, as this immunohistochemical marker shows cell proliferation activity, it is of great importance not only in tumor processes, but also in hyperplasia, metaplasia, regeneration, and dysplasia, which continue with cell proliferation.

Cell proliferation index can be calculated based on the Ki-67 marker. A total of 500 cells were counted in the calculation, and it was determined how many of them had the positive expression of this marker in the nucleus, and what percentage of all cells were positive. 1) 10% - low level, 2) 10-20% - medium level, 3) more than 20% is considered high level expression.

Taking into account the above discussion, the aim of this study was to determine the expression level and proliferation index of Ki-67 in papillary, follicular, medullary and undifferentiated carcinomas of the thyroid gland.

The next task is to study the protein R53 as a transcription factor and a protein that controls the cell cycle by immunohistochemical method. R53 is a gene suppressor in tumorigenesis. This protein is mutated in 50% of malignant tumor cells. This gene has several names: r53 cellular tumor antigen, tumor suppressor r53, r53 phosphoprotein, NY-CO-13 antigen. Normally, the R53 tumor suppressor gene is expressed in all cells of the body. If the genetic apparatus of the cell is not damaged, r53 is inactive, and if DNA is damaged, r53 is activated. Thus, p53 is activated when DNA-damaging factors accumulate. Activation of R53 results in cell cycle arrest and apoptosis. R53 is known to be activated in several precancerous diseases, including chronic inflammatory, dysregenerative, and precancerous diseases of the bladder. The concentration of p53 protein increases especially in

proliferative and multiplying cells, especially when hyperplasia and proliferation of cells, which is a disregenerative process, increases. The significance of the increased concentration of R53 is that it rapidly replicates with DNA and damages the gene machinery, and this state is the preparation of the cell for DNA damage. In intact, well-differentiated cells, the latent r53 protein is located in the cytoplasm of the cell. When the proliferative activity of the cell increases, this p53 protein moves to the nucleus, and in the absence of stress effects on the cells, this protein is degraded in 5-20 minutes.

Our next task was to study thyroid transcription protein TTF-1, a protein product expressed in thyroid follicular epithelium and S-cells. This protein is a protein that induces the expression of a group of genes that ensure thyroid follicular epithelium and S-cell differentiation. Therefore, due to the development of malignant tumors from follicular cells and interstitial S-cells in malignant tumors of the thyroid gland, it is of great importance to study the group of genes that ensure their differentiation by immunohistochemical method.

PAPILLARY CARCINOMA

The results of the investigation showed that the expression of the cell proliferation factor in papillary carcinoma was found to have different indicators in the epithelial cells and interstitial cells of the tumor we studied. It is determined that it is expressed in light brown in most of the tumor epithelial cells, in some cells it is dark brown. It was found that expression of Ki-67 marker in tumor cells was moderate, proliferative index was 21.4% (Fig. 1). In this case, the expression of the nuclei of epithelial cells both in the karyoplasm and the nucleus confirms that the cells are in the middle phase of activation, that is, in the G2 phase. Immunohistochemical examination of the Ki-67 marker showed that a significant number of hyperplastic and irregularly located papillary carcinoma cells are expressed in the nucleus of a significant number of cells in the form of dark brown color. In this case, some nuclei are enlarged and this marker is expressed both in the karyoplasm and the nucleus (Fig. 1). It is determined that the size of the nuclei of other cells is relatively small and they appear in a relatively light brown color. Expression of the Ki-67 marker at different levels indicates that these cells are activated at different levels of mitotic and proliferative activity.

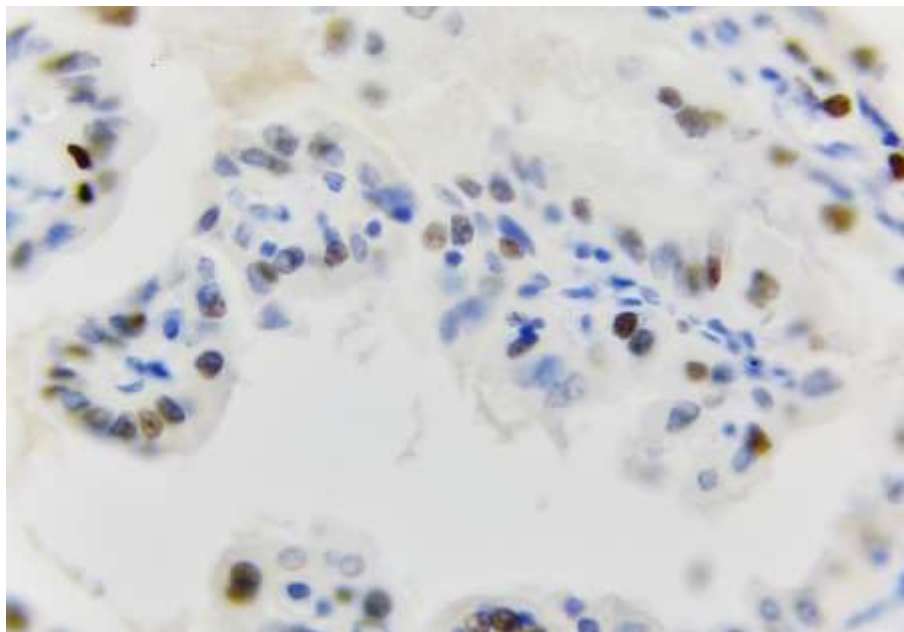


Figure 1. Papillary carcinoma, moderately positive expression of Ki-67 marker (1). Paint: Dab chromogenic. Size: 10x40.

In order to determine the pathomorphological and immunohistochemical changes occurring in the papillary carcinoma epithelium, biopsy material obtained from people without any pathology in the thyroid gland was studied as a control group. Then, the pathomorphological and immunohistochemical changes in the epithelium of different histological

variants of papillary carcinoma were compared. It is determined that the epithelium of the thyroid gland follicles of the control group consists of a single-layered prismatic epithelium, and its epithelial cells located in the basal layer are relatively large, hyperchromic, arranged in the basement membrane, most of their nuclei are elongated and elongated. In

the surface layers of the epithelium, it is observed that the cells are relatively sparse, their nuclei are smaller in size, their color is lighter, and their location is flattened. The results of the immunohistochemical examination of r53-protein, which controls the cycle of cell division and reproduction of the epithelial cell, preventing it from turning into a tumor, that is, the gene suppressor, showed that in the control group, some cells of the cambial level, located only in the basement membrane, are relatively young and have the characteristics of dividing and multiplying, and the cytoplasm is at a very low level in the nucleus of others. it is observed that this protein is expressed, but not expressed in the cells of other intermediate and surface layers. Microscopic examination showed that in the cells of the basal layer of the thyroid epithelium in the control group, the r53-gene

suppressor was located in the cytoplasm of some cells, and in the nucleus of most cells (Fig. 2). This situation indicates that some of the cambial cells located in the basal layer are in a proliferative active state and it is confirmed that the r53 gene suppressor is replicated with the DNA protein in their nucleus.

A study of the thyroid transcription protein TTF-1, a protein product expressed in the thyroid follicular epithelium, was obtained.

In this papillary carcinoma, it was observed that a protein that induces the expression of a group of genes that ensures the differentiation of thyroid follicular epithelial cells is expressed. In this case, TTF-1 protein expressed at a low level in follicular epithelial cells located in papillary carcinoma nipples indicates a low level of differentiation of these cells (Figure 3).

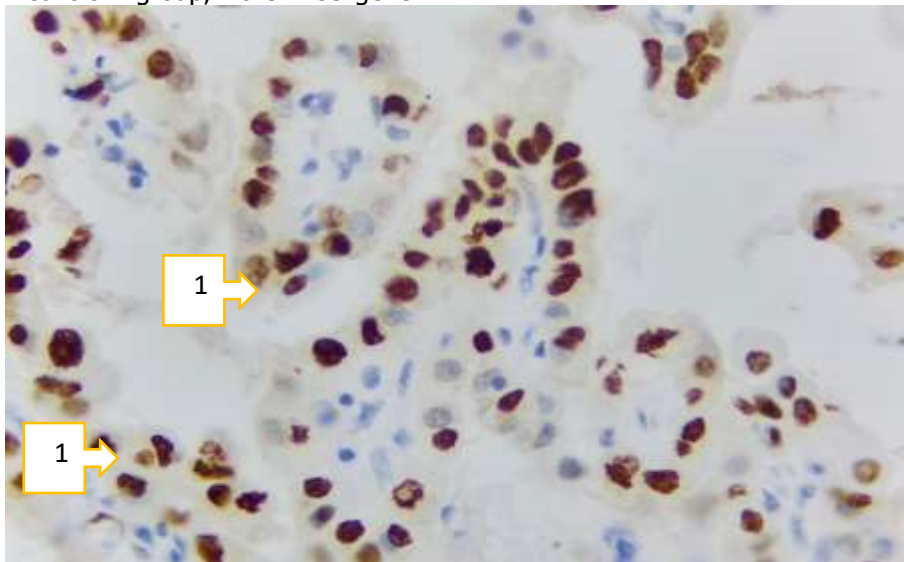


Figure 2. Papillary carcinoma, positive expression of r53 marker (1). Paint: Dab chromogenic. Floor: 10x40.

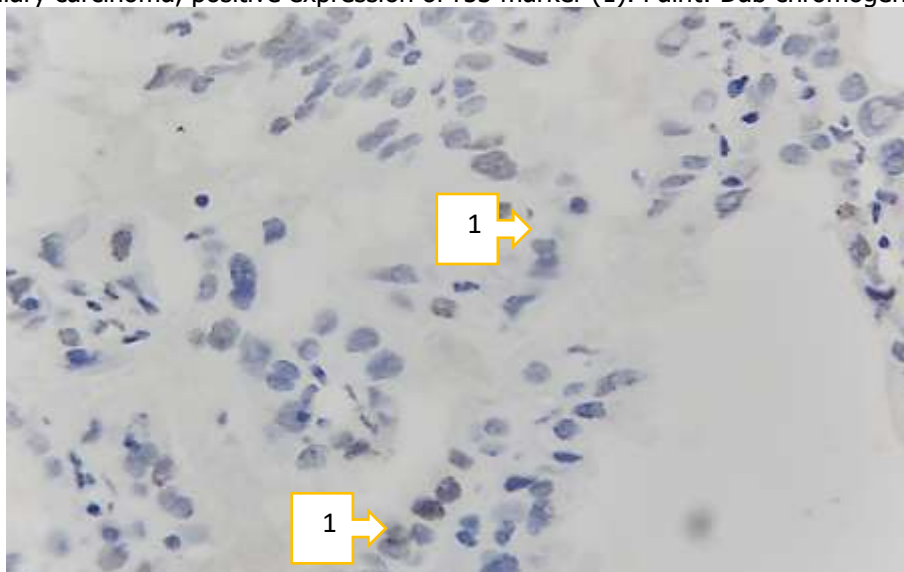


Figure 3. Low expression of follicular epithelial TTF-1 protein in papillary carcinoma(1). Paint: Dab chromogenic. Floor: 10x40

FOLLICULAR CARCINOMA

Follicular carcinoma was examined by immunohistochemical method, that is, expression of the Ki-67 marker was found to be expressed in dark brown in most tumor cells, and light brown in some cells. When calculating the proliferation index of tumor cells based on the Ki-67 marker, a total of 500 cells are counted. The number of positively expressed cells in follicular carcinoma was 231, i.e. 46.2%. This confirms that the proliferation index of tumor cells in follicular carcinoma is high. In this case, the expression of the nuclei of epithelial cells both in the

karyoplasm and the nucleus confirms the middle phase of cell activation, i.e., G2, G3 phases. Immunohistochemical examination of the Ki-67 marker showed that a significant number of hyperplastic and irregularly located follicular carcinoma cells express a dark brown color in the nucleus (Figure 4). In this case, some nuclei are enlarged and this marker is expressed both in the karyoplasm and the nucleus. Expression of the Ki-67 marker at different levels indicates that these cells are activated at different levels of mitotic and proliferative activity.

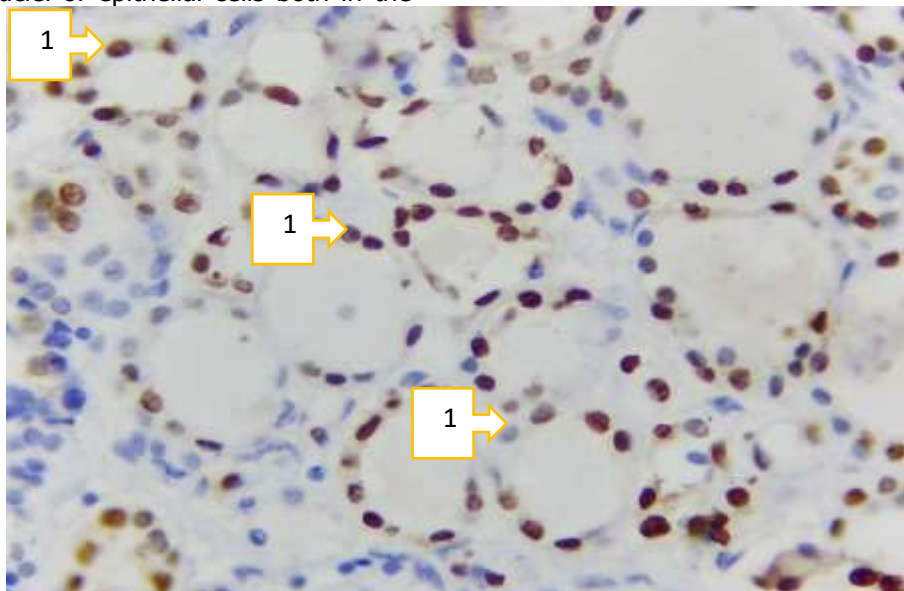


Figure 4. Follicular carcinoma, high expression of Ki-67 marker (1). Paint: Dab chromogen. Floor: 10x40.

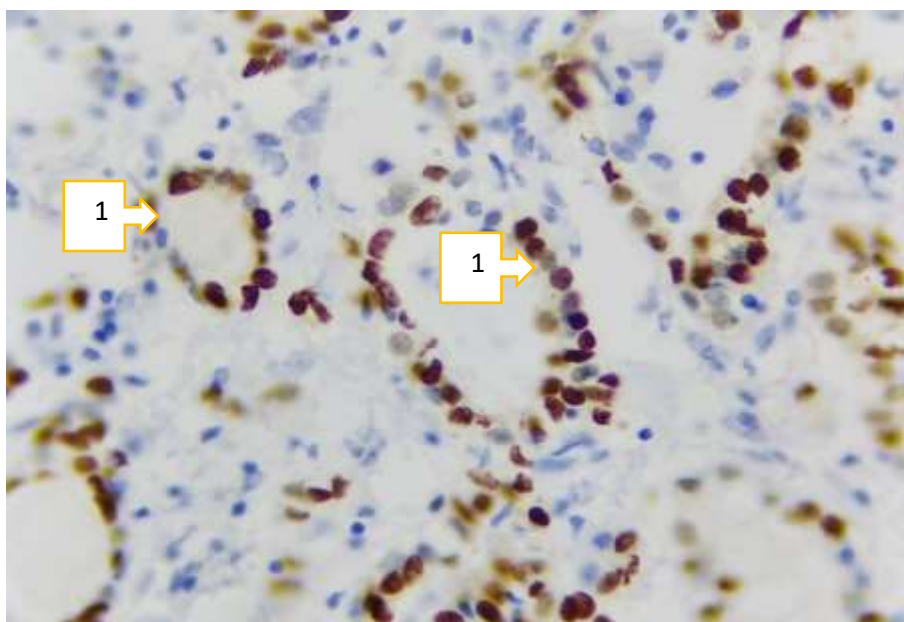


Figure 5. Follicular carcinoma, r53 marker expression level (1). Paint: Dab chromogen. Floor: 10x40

A protein called R53 is known to be a transcription factor that controls the cell cycle. This protein is mutated in 50% of malignant tumor cells, which means that the R53 marker plays the role of a gene suppressor in the formation of a malignant tumor. According to the authors, r53 is passive when the cellular genetic machinery is not damaged, and r53 is activated when DNA is damaged. When the follicular carcinoma tumor tissue was studied to determine the r53 marker, it became clear that because the tumor follicles were of different sizes, the expression of this marker was also found to be at different levels. It was observed that it was mainly expressed in the nuclei of the cells in a dark brown color (Figure 5). In the cytoplasm of some cells, it was expressed at a

relatively low level in the light brown state. When counting the cells expressing the r53 marker, if their number increases by 25%, it is considered positive. In our material, it was 38.5%, which is a strong positive level of expression.

In thyroid follicular carcinoma cells, it was observed that the expression of thyroid transcription protein TTF-1 was relatively weak. In follicular carcinoma, it was observed that it is expressed as a protein that induces the expression of a group of genes that ensure the differentiation of thyroid follicular epithelial cells. TTF-1 protein expressed at a relatively low level in follicular epithelial cells in follicular carcinoma follicles indicates the average level of differentiation of these cells (Figure 6).

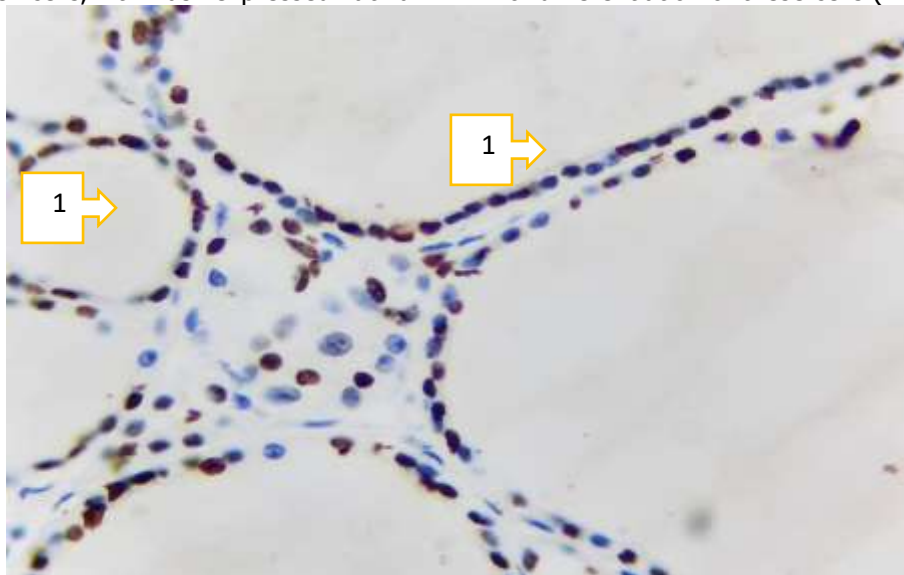


Figure 6. Follicular carcinoma, TTF-1 marker expression level (1). Paint: Dab chromogen. Floor: 10x40.

Medullary carcinoma.

Since medullary carcinoma of the thyroid gland develops from S-cell, Ki-67 is expressed in it at different levels in all phases of cell activation, i.e. G1, S, G2, M. The expression level of Ki-67 increases from the initial G1 phase of cell activation to the final M phase and reaches a maximum at the metaphase of mitosis. In the middle phases of cell activation, the Ki-67 marker appears in the nucleus, and by the G2

phase, it is expressed both in the nucleus and in the karyoplasm. Therefore, this immunohistochemical marker is of great importance in the assessment of malignant tumors because it shows the proliferation activity of the cell. When studied morphometrically, it was found that the proliferation index of tumor cells in medullary carcinoma tissue was low at 9.6% (Figure 7).

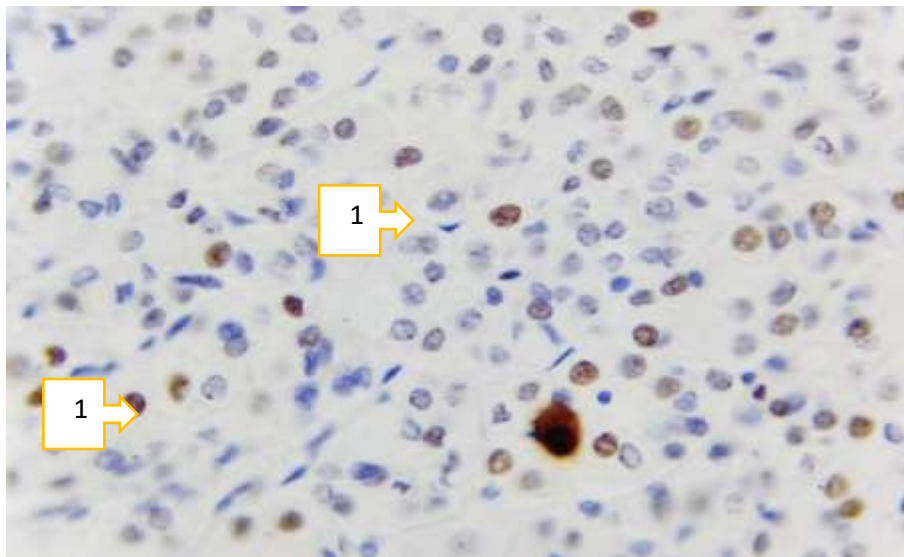


Figure 7. Expression level of Ki-67 marker in medullary carcinoma. Paint: Dab chromogen. Floor: 10x40.

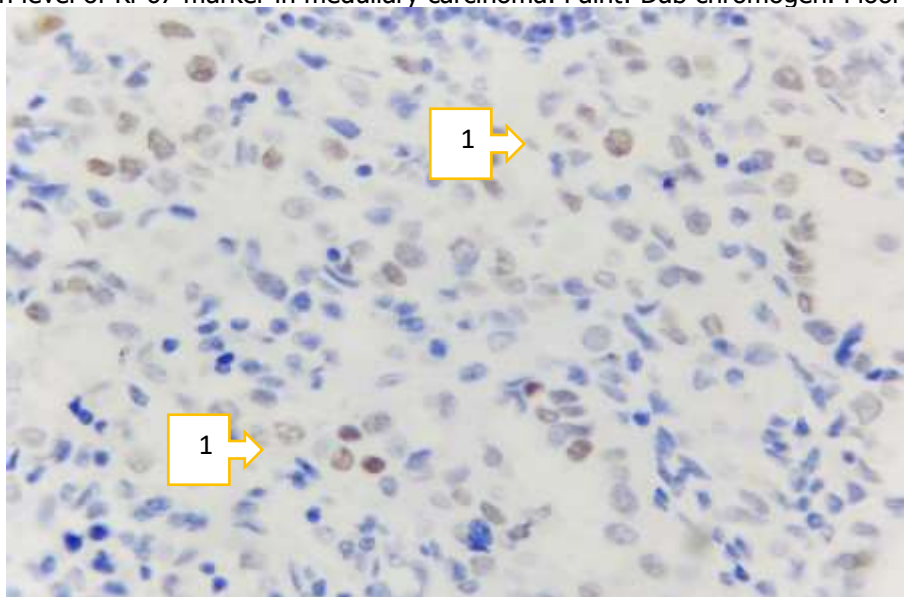


Figure 8. Medullary carcinoma, r53 marker expression level. Paint: Dab chromogenic. Floor: 10x40

Studying the level of expression of the p53 marker in medullary carcinoma of the thyroid gland showed that the proliferation and proliferation of S-cells in this tumor is strong, which indicates an increase in the protein related to this marker. This

marker is positively expressed as a result of DNA replication in the nucleus of cells. In our material, more than 50% of the cells in medullary carcinoma tissue had a positive expression of the r53 marker, albeit at a low level (Fig. 8)

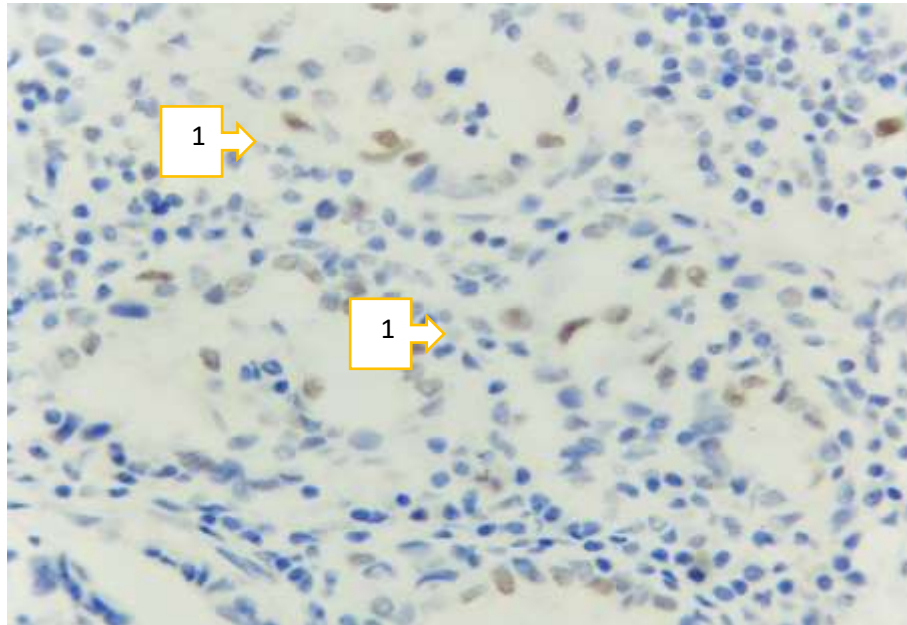


Figure 10. Expression level of TTF-1 marker in medullary carcinoma. Paint: Dab chromogenic. Floor: 10x40.

In medullary carcinoma, it was observed that expression of thyroid transcription protein TTF-1 in thyroid tissue S-cells was relatively weak. In this case, it was observed that it is expressed in both the nucleus and cytoplasm of the cell as a protein that induces the expression of a group of genes that ensure the differentiation of S-cells. TTF-1 protein expressed at a relatively low level in cells indicates the average level of differentiation of these cells (Fig. 10).

Undifferentiated anaplastic carcinoma

It is known that the Ki-67 marker is a marker of proliferation of any cells, so the proliferation of tumor cells in undifferentiated carcinoma is high. As a result, this marker is activated during the last phases of cell division. In our material, it is observed that Ki-67 marker is expressed in light and dark brown color in poorly differentiated, polymorphic tumor cells (Fig. 11). Its proliferation index of 16.3% is determined to be medium.

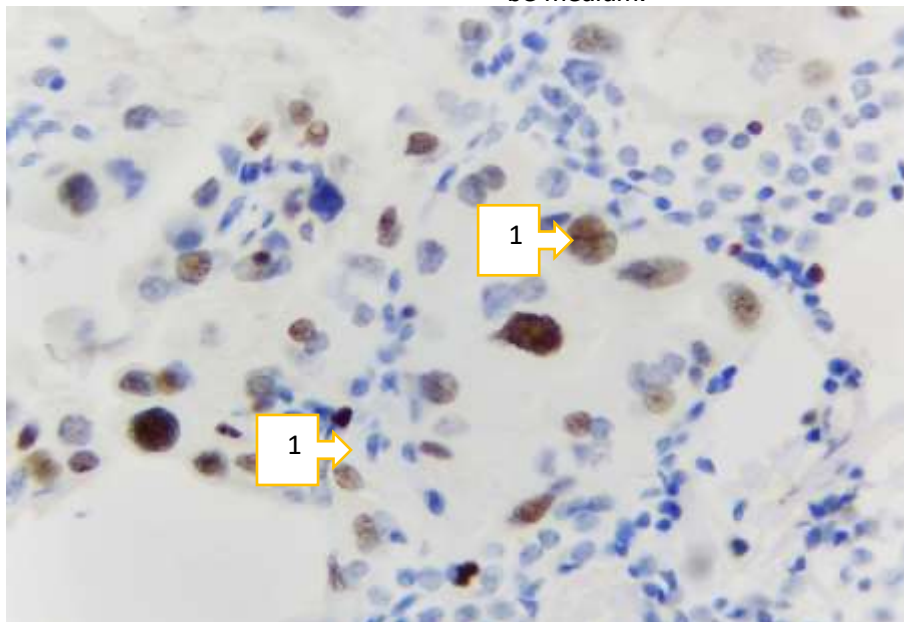


Figure 11. Undifferentiated carcinoma, positive expression of Ki-67 marker (1). Paint: Dab chromogenic. Floor: 10x40.

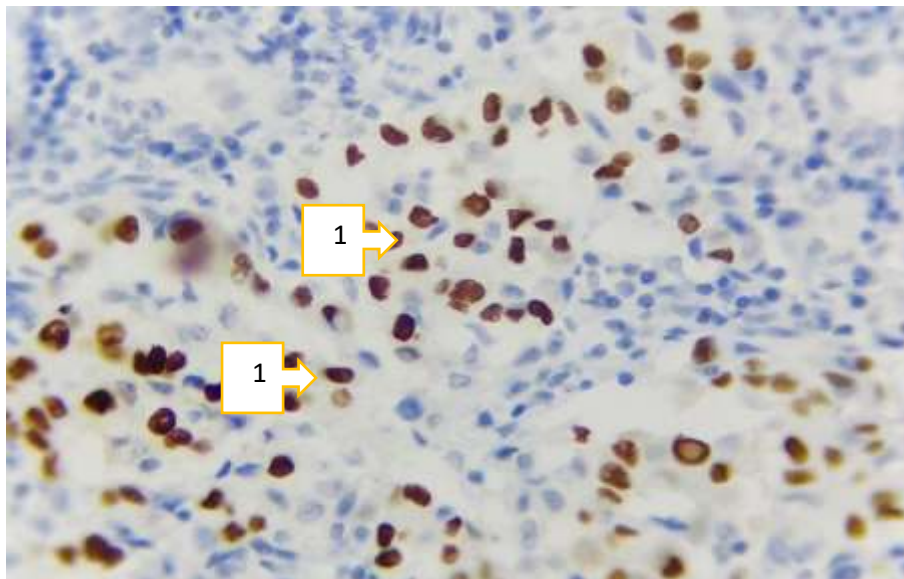


Figure 12. Undifferentiated carcinoma, expression level of the r53 marker (1). Paint: Dab chromogen. Floor: 10x40.

In poorly differentiated carcinoma, the degree of anaplasia of tumor cells is strong, young and polymorphic cells appear, positive expression of the gene suppressor r53 in them indicates that the DNA of tumor cells is damaged. In our material, it is

determined that this marker is positively expressed in cells with strong atypism in poorly differentiated carcinoma (Fig. 12), and the number of positively expressed cells is 31.3%, which indicates that its index is moderately increased.

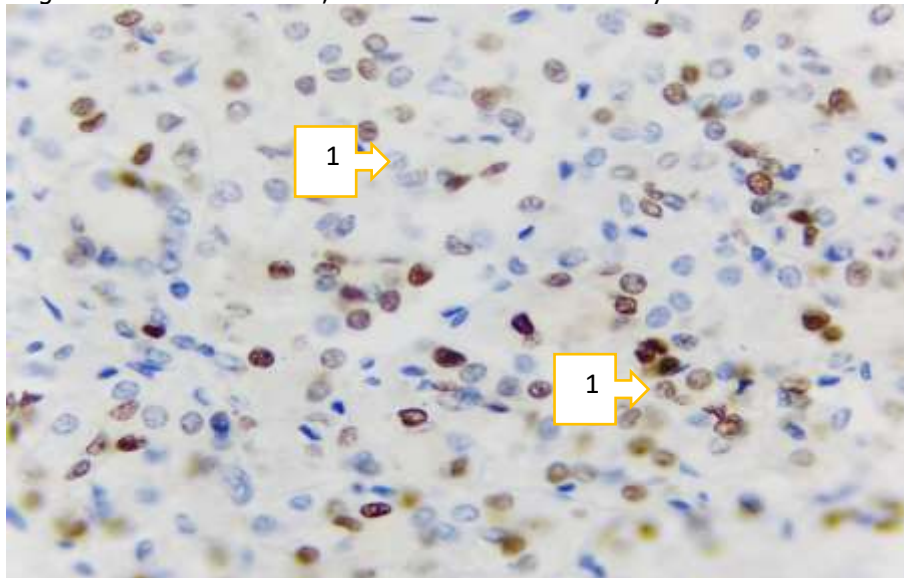


Figure 13. Low-differentiated carcinoma, TTF-1 marker expression level. Paint: Dab chromogen. Floor: 10x40.

In poorly differentiated carcinoma, the differentiation of tumor cells is completely paralyzed, and due to the proliferation of polymorphic tumor cells during anaplastic and cataplastic processes, it is found that the expression of thyroid transcription protein TTF-1 is slightly increased (Fig. 13). It was observed that the protein TTF-1, which induces the expression of a group of genes that ensures the differentiation of tumor cells, is expressed in both the nucleus and the cytoplasm of the cell. Moderately expressed TTF-1

protein in cells indicates a relatively high degree of differentiation of these cells.

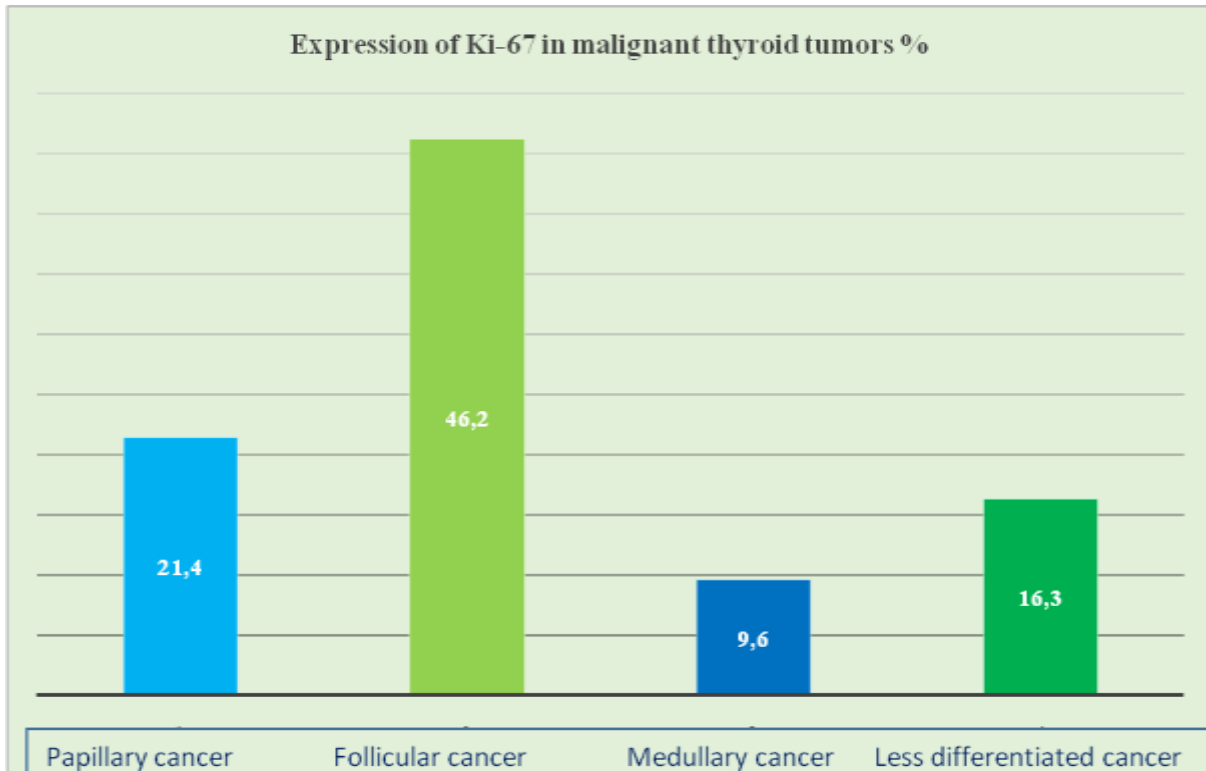
When calculating the proliferation index of cells based on the Ki-67 marker in various types of malignant thyroid tumors, it was found that the highest index was in follicular carcinoma, the lowest index was in medullary carcinoma and poorly differentiated carcinoma (Graph 1).

The highest level of expression of the R53 gene suppressor was found in medullary carcinoma, the lowest in papillary carcinoma, and moderate levels

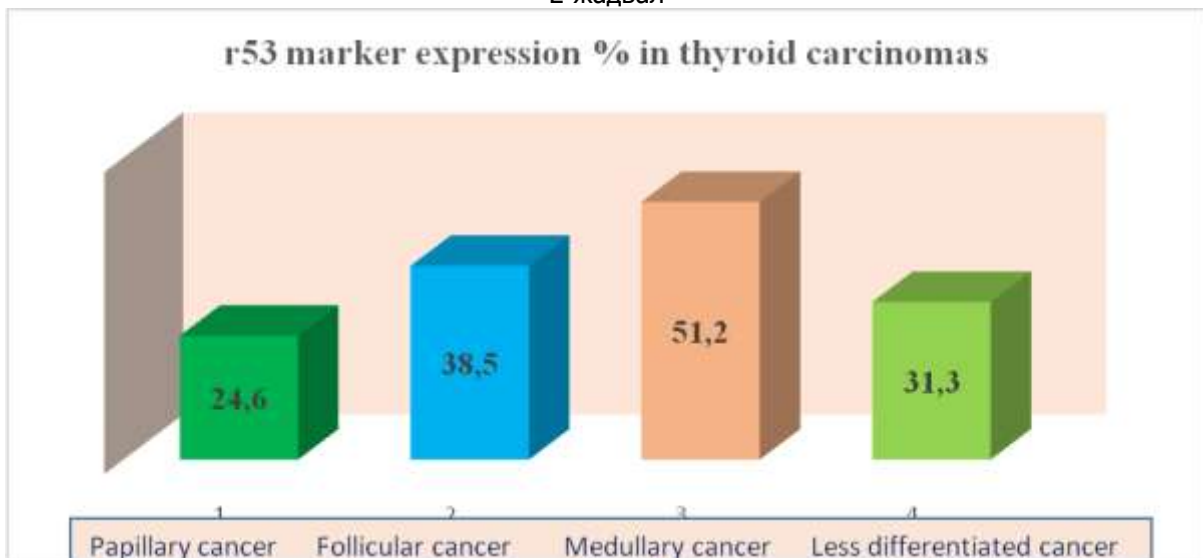


in follicular and poorly differentiated carcinoma (Graph 2).

1-table



2-жадвал



CONCLUSION

In papillary carcinoma of the thyroid gland, Ki-67, a marker of cell proliferation index, showed an average level, r53 marker gene suppressor was expressed at a high level, thyroid transcription protein TTF-1 was observed to be expressed at a low level in the follicular epithelium.

In follicular carcinoma, the cell proliferation index was very high, the gene suppressor r53 marker

was moderately expressed, and the follicular epithelial thyroid transcription protein TTF-1 was proved to be low-expressed.

All immunohistochemical markers, including Ki-67, r53 and TTF-1, were found to be low-expressed in medullary carcinoma.

In poorly differentiated carcinoma of the thyroid gland, it was confirmed that the cell proliferation index was moderately expressed, the r53



gene suppressor was moderately expressed, and the thyroid transcription protein TTF-1 was moderately expressed.

REFERENCES:

1. Agarwal S, Bychkov A, Jung CK. Emerging Biomarkers in Thyroid Practice and Research. //Cancers (Basel). 2021 Dec 31;14(1):204.
2. Dell'Aquila M, Granitto A, Martini M, Capodimonti S, Cocomazzi A, Musarra T, Fiorentino V, Pontecorvi A, Lombardi CP, Fadda G, Pantanowitz L, Larocca LM, Rossi ED. PD-L1 and thyroid cytology: A possible diagnostic and prognostic marker. //Cancer Cytopathol. 2020 Mar;128(3):177-189.
3. Caulley L, Eskander A, Yang W, Auh E, Zafereo M, Stack BC Jr, Randolph G, Davies L. Trends in Diagnosis of Noninvasive Follicular Thyroid Neoplasm With Papillarylike Nuclear Features and Total Thyroidectomies for Patients With Papillary Thyroid Neoplasms. //JAMA Otolaryngol Head Neck Surg. 2022 Feb 1;148(2):99-106.
4. French B, Hattier G, Mardekian SK. Utility of Tumor Capsule Thickness as a Predictor of Invasion in Encapsulated Follicular Variant of Papillary Thyroid Carcinoma and a Diagnostic Tool for Noninvasive Follicular Thyroid Neoplasm With Papillary-Like Nuclear Features.// Int J Surg Pathol. 2020 Feb;28(1):13-19.
5. Yang H, Chen L, Cheng Z, Yang M, Wang J, Lin C, Wang Y, Huang L, Chen Y, Peng S, Ke Z, Li W. Deep learning-based six-type classifier for lung cancer and mimics from histopathological whole slide images: a retrospective study. //BMC Med. 2021 Mar 29;19(1):80
6. Zhu X, Chen C, Guo Q, Ma J, Sun F, Lu H. Deep Learning-Based Recognition of Different Thyroid Cancer Categories Using Whole Frozen-Slide Images. //Front Bioeng Biotechnol. 2022 Jul 6;10:857377.
7. Boursier L, Clerc Urmes I, Garon J, Klein M, Demarquet L. Ultrasound and cytological characteristics of non-invasive follicular thyroid neoplasm with papillary-like nuclear features compared to papillary carcinomas. //Ann Endocrinol (Paris). 2020 Feb;81(1):28-33.
8. Rosario PW, Mourão GF. Noninvasive follicular thyroid neoplasm with papillary-like nuclear features (NIFTP): a review for clinicians.// Endocr Relat Cancer. 2019 May 1;26(5):R259-R266.
9. Kholová I, Haaga E, Ludvik J, Kalfert D, Ludvikova M. Noninvasive Follicular Thyroid

Neoplasm with Papillary-like Nuclear Features (NIFTP): Tumour Entity with a Short History. A Review on Challenges in Our Microscopes, Molecular and Ultrasonographic Profile. //Diagnostics (Basel). 2022 Jan 20;12(2):250.