



DEVELOPMENT OF THE MICROVASCULAR BED AND TISSUE STRUCTURES OF THE LARGE INTESTINE DURING PROLONGED PESTICIDE POISONING

Nosir A. Khasanov Senior Lecturer of the Department of Human Anatomy and OSTA of the Tashkent Medical Academy. Tashkent, Uzbekistan, nosirhasanov9@gmail.com;

Khabibulla Kh. Pulatov Associate Professor of the Department of Human Anatomy and OSTA of the Tashkent Medical Academy. Tashkent, Uzbekistan, habibulopulatov3@gmail.com;

Behzod Kh. Shermatov Senior Lecturer of the Department of PVB, Rehabilitology, Traditional Medicine and Endocrinology, Termizi Branch of the Tashkent Medical Academy. Tashkent, Uzbekistan, bshermatov21@gmail.com;

Akhror U. Khujabekov Head of the Department of Internal Medicine of the University of Physical Education and Sports of Uzbekistan, xaxrorjon55@gmail.com.

Article history:

Received: March 20th 2023
Accepted: April 22nd 2023
Published: May 24th 2023

Abstract:

The ongoing worldwide intensive chemicalization of agriculture leads to the fact that annually a large number of various foreign chemicals (xenobiotics), including pesticides, enter the planet's biosphere, that is, the environment for the habitat of all living things, including humans.

As a result of careless handling of pesticides, as well as accidental or intentional ingestion of the drug, acute and subacute poisoning occurs [1].

Most researchers [1] note that in acute poisoning with pesticides, especially insecticides and acaricides, there is an increased blood filling of intraorgan vessels, swelling of their walls and hemorrhage in the gastrointestinal mucosa.

We have studied the effect of new pesticides "Neoron" and "Sumi-alpha" on the morphological state of the microvasculature and tissue structures of the colon in acute poisoning. LD50 for rats with intragastric administration of "Neoron" was 950 mg/kg and "Sumi-alpha" - 75 mg/kg, respectively. The drugs were administered once intragastrically using a metal probe at a dose of 1/2 LD50. at the rate of 1.0 ml of an aqueous solution of the pesticide per 100 animal weight. Control animals in the same volumes received distilled water at the rate of 1.0 ml per 100 weight.

Keywords:

THE RELEVANCE OF THE WORK.

Among the complex of anthropogenic factors, pesticides are important, which, due to large volumes of production and use, pose a potential threat both to the environment, causing the development of an ecological imbalance of biocenoses, and to the human body, leading to pathological changes in individual body systems: a decrease in immune resistance, the emergence of malignant neoplasms, autoimmune processes, allergies, the development of pathology of the gastrointestinal tract (GIT) (Speranskaya O.A., 2004; Zeise L., 2013). Every year, about 0.5-0.6 million cases of poisoning with agrochemicals are recorded worldwide, 10% of which are fatal (Kulaev K.T., 2013; Omarova Z.M., 2011). One of the most actively used groups of pesticides are insecticidal

preparations (more than 14% of the total volume of used agrochemicals), which have a powerful effect against harmful insects (Kuzmicheva L.V., 2010; Soldatenkov A.T., 2012; Sergeev V.R., 2009). Among the variety of insecticidal preparations, both in Russian and international practice, bankol (the active substance bensultap), which the World Health Organization (WHO) classifies as hazard class III, is dominant in use (Ilnitskaya A.V., 2006; Kvashnin Yu.A., 2011). Due to the fact that the drug is able to persist for a long time in the products of primary processing of agricultural crops and has high cumulative and toxic properties, it can be an environmental hazard for both animals and humans. Since the main source of pesticides entering the human body is food, with which about 80-85% of all



chemicals are supplied, as a result, damage to the organs of the gastrointestinal tract is possible (Panina N.K., 2010; Shormanov V. K., 2010; Eldafravi B.M., 2010; Korolev V.A., 2012;). The lack of information about the environmental risks of the formation of gastrointestinal pathology, as well as morphological changes in the digestive tract, their prevention and correction during insecticidal intoxication explains the relevance of this study. In order to study various pathological processes in medicine, experimental models are used in which experimental animals are involved. Among the chemicals that pollute various environmental objects, including the air of the working area, atmospheric air, water bodies, soil, food products, pesticides form a significant group. Of the various chemical compounds used in the fight against pests of agricultural crops, pesticides of the pyrethroid group have received the most widespread use at the present time [25, C.7-9; 168, S.43-46]

In recent years, the violation of immunoregulatory processes in the human body leads to the growth of infectious, allergic, autoimmune, lymphoproliferative and malignant diseases [18, p.25-28; 82, pp. 109-111; 86, 161-s]. Pesticides are considered one of the most dangerous environmental pollutants. However, despite this, in recent decades, pesticides have become a necessary component of agricultural production [90, p.845; 175, S.109-112].

Synthetic pyrethroids are promising pesticides with pronounced insecticidal activity, low volatility, instability under the influence of various factors [100, p.102-107]. Pyrethroids are used in agriculture as a broad-spectrum insecticide, including for the control of household insects. The production and widespread use of pesticides has led to environmental pollution: soil and water reservoirs. Currently, various chemicals are used in agriculture for the processing of grape, vegetable and especially cotton fields. Since pesticides have a different chemical nature, it is of great interest to study their effect on the human and animal organisms. The intensive use of pesticides in the national economy has led to their accumulation in the environment and food. The developed rules and measures applied in the national economy aimed at reducing the likelihood of pesticides entering and accumulating in the environment, food products and medicinal plants cannot fully solve this problem [190; dis.].

The mechanism of the toxic action of many chemical groups of pesticides has been studied to a greater or lesser extent, on the basis of which their modern regulation in environmental objects is based, preventive measures are being developed to prevent negative effects on the human body, and antidote therapy is being sought.

From the foregoing, it follows that at present there is a need for a detailed study of the effect of pesticides on the human body and animals, including the effect of pyrethroid pesticides on the organs of the gastrointestinal tract. An analysis of the literature shows that pesticides have a general toxic effect, have a long-term mutagenic, embryotoxic, gonadotropic, teratogenic and blastomogenic effects, the severity of which depends on the chemical nature of the toxin, the duration of exposure, dose, the state of the body's detoxification mechanisms and many other factors.

Violations of microcirculation and tissue pathologies are included as an important pathogenetic link in a number of typical pathological processes and in many particular pathological forms. In this regard, taking into account microcirculation disorders is important for elucidating the mechanism of development of various pathological processes.

It can be assumed that the violation of microcirculation is the most important link in that vicious circle, which in the end leads to the breakdown of compensatory and adaptive reactions and the body's capabilities (2,3,43,51).

THE PURPOSE OF THIS STUDY:

In this regard, we made an attempt to study morphological changes in tissue structures simultaneously with the study of the state of the vessels of the microcirculatory bed of the large intestine in rats with sequential poisoning with pesticides Neoron and Sumi alfa.

MATERIAL AND METHODS OF RESEARCH:

The experiment was carried out on 67 (50) adult outbred rats, 30 days after the creation of the model, which for 15 days were intragastrically injected daily on an empty stomach with a solution of "Neoron" at a dose of 1/20 LD 1.0 ml/100 g of mass, and in the next 15 days in the same way - "Sumi-alpha". The observation period was 90 days after inoculation.

To study the intraorganic vessels of the large intestine, the method of transcapillary injection of vessels with the mass of Gerota through the thoracic aorta was used in the modification of Kh. Kh. Kamilov [14]. Then the organocomplex was fixed in 10% neutral formalin

solution for 5 or more days. To study the vessels, transverse sections were taken from the blind, (proximal, middle and distal) colon, which were clarified in alcohols of increasing concentration according to the accelerated method of A. M. Malygin [22], and also according to the method of T. A. Sagatov [41, 42]. Циркулярные срезы толщиной 60-120 мкм заключали в бальзам. Проводили также импрегнацию различных слоев толстой кишки нитратом серебра по методу В. В. Куприянова [11,12].

Before impregnating a piece of the colon with silver nitrate, its film material was fixed in a solution of 12% neutral formalin (at least 7 days). From the fixed pieces of this organ, sections were prepared on a freezing microtome with a thickness of 10–20 µm. Sections, film material corresponding to the impregnation with silver nitrate were dehydrated with alcohol, carbol-xylene, and then placed in a balm.

For general morphological studies, tissue pieces from 4 sections (blind, proximal, middle, and distal) of the large intestine were fixed in a neutral 10% formalin solution, Carnoy's fluid. After appropriate wiring, the material was embedded in paraffin. Further, sections with a thickness of 4–6 µm, with the strictest orientation, were stained with hematoxylin-eosin after deparaffinization for general morphological and morphometric studies.

For electron microscopy, samples of the mucous membrane of various parts of the rat colon were fixed in 1% buffered glutaraldehyde solution, additional fixation was carried out in 1% osmium tetroxide (OsO₄) for 1.5-2 hours at a temperature of 4°C (pH - 7.3-7.5). After dehydration in alcohols of increasing concentration, tissue pieces were poured into an eponaldite mixture. After contrasting with uranyl acetate and lead nitrate, ultrathin sections were examined under a Hitachi H-600 electron microscope (Japan).

For scanning electron microscopy [46], the vessels of the large intestine were filled with polymerized methacrylate, then the corrosion casts after deposition of a thin layer of gold in an IB-3 sprayer were examined in an S-405 electron microscope of the same laboratory.

Morphometrically, using an MBR-1-15 eyepiece micrometer, the thickness of the wall membranes of 4 sections of the colon and the diameters of the vessels of the microvasculature of the blind, proximal, middle, and distal sections of the colon were measured; using the method of A. A. Gutsol et al. [9], the total specific density of distribution of microvessels per 1 mm² was determined. Statistical processing of the obtained

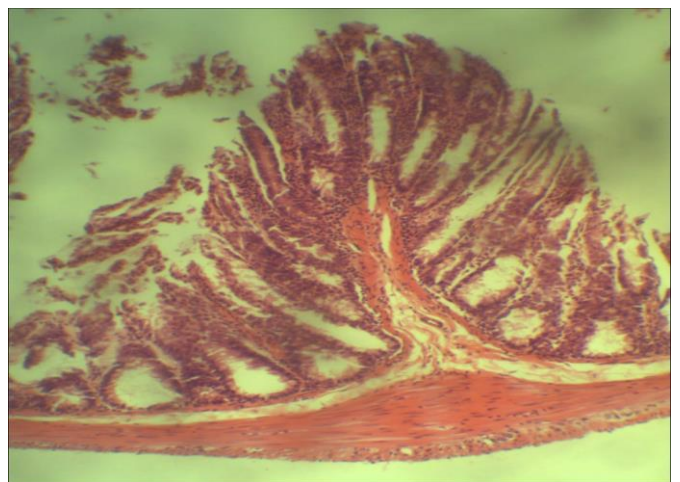
results was carried out using standard methods of variation statistics using Student's t-test to assess the significance of differences using the Excel - 2000 program on an IBM PC computer. Mean values are presented as Mm (meanmean error of the mean). Differences were considered significant at P<0.05.

RESEARCH RESULTS AND DISCUSSIONS

3 days later, expansion and blood filling of the vessels of the serous-muscular membrane were established, there were ruptures of vessels and hemorrhages. Swelling and infiltration of the serous-muscular membrane is more pronounced, loosening of muscle tissue has increased. Morphometric parameters of the microvasculature of the serous and muscular membranes differ from the control value by 1.4-1.6 times. The capillaries are plethoric, dilated, arranged in a sinuous manner.

In the submucosa, swelling and loosening continue, its thickness throughout the colon has increased, expansion of ordinal vessels is observed, and in some places there are extravasations.

The mucous membrane is swollen and infiltrated, in some places there are atrophied cellular elements. The thickness of the mucous membrane is up to 435.0+-21.18 microns in the proximal, up to 455+-24.64 microns in the middle and 327+-16.3 microns in the distal parts of the intestine. (normally 41.45364 + -



21.11 microns).

Quantitative and qualitative changes in epithelial cells lead to a decrease in the depth of the crypts, sometimes covered with low-prismatic epithelium, there are areas with indistinguishable nuclei, the brush border is thinned. The stroma of the crypts is edematous. There is lymphocytic infiltration of the own layer of the mucous membrane and the stroma of the crypts.

Among the swollen cells there are pyknotically altered nuclei; in some cells, the nuclei are located eccentrically. The microcirculatory bed is a functional system, the main task of which is the material provision of organs and tissues in accordance with their physiological characteristics and functional state. [41,45,63].

Consequently, the microcirculatory system is an integral component of the functional unity of the organ and its constituent cell systems (tissues).

The microvessels of the mucous membrane are filled with blood, in some places they are sinuously located, there are extravasations. The density of blood vessels increased. In the crypts, the precapillaries are filled with blood, eccentrically located, and blood cells are found at the mouth of the crypts.

After 7 days, most of the microvessels of the serous-muscular membrane were filled with blood, sinuously located, spasmodically narrowed microvessels were encountered. The ordinal vessels of the venous plexus in the submucosa are varicose.

Crypts of unequal height, thinned, look like narrow cylindrical tubes, their lumen is narrowed. The depth of the crypts was $315.9 \pm 17.4 \mu\text{m}$.

Enterocytes in the longitudinal section of the crypts have a low-prismatic shape, their number decreased to 24.0 ± 0.3 and 20.4 ± 0.3 , respectively (35.4 ± 1.2 in control).

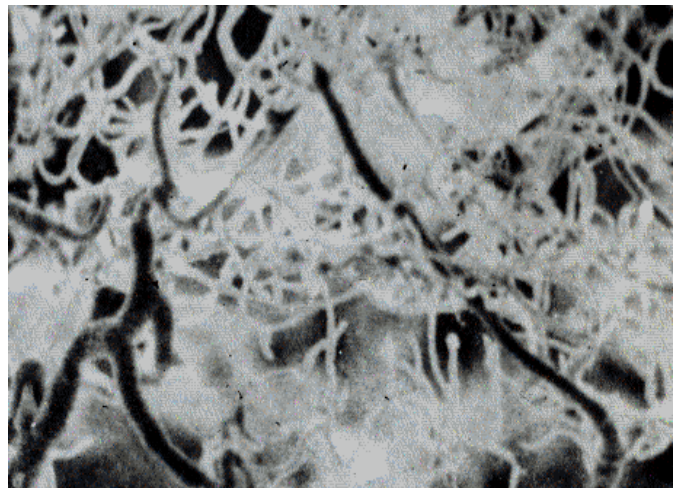
Among crypt enterocytes there are cells with large nuclei that occupy almost the entire cell body. The crypts also showed a decrease in the number of goblet cells, 49.8 ± 1.91 (36.0 ± 1.69 in control).

Vessels of the mucous membrane of the colon are in a different state. 6..3. The lumen of all departments of the microvasculature is significantly ($P < 0.001$) wider than in the comparison group. The precapillaries are tortuous, their inner lumen is the same. In the mucous membrane of the colon, the size of the lumen of microvessels is noticeably larger than in the comparison group. The diameter of precapillaries in sequential poisoning with Neoron acaracite and Sumi_alfa insecticide is $18.29 \pm 1.10 \mu\text{m}$ ($14.84 \pm 0.80 \mu\text{m}$ in control). as well as capillaries were found with a noticeably reduced diameter. The precapillaries are tortuous and filled with blood. Their lumen diameter increased by 1.20 times in all parts of the large intestine compared to the control (table). In some areas, stases and microthrombi were found in the lumen. The walls of the postcapillaries are thinned, the lumens are dilated and filled with blood. Their lumen diameter increased by 1.34 times compared to the control.

After 15-30 days, destructive-dystrophic phenomena intensified. In the lumen of the crypts, elements of tissue detritus and mucus were detected.

In the mucous membrane, dyscirculatory disorders were aggravated. In some crypts, avascular- or low-vascular zones were often observed, the number of blindly ending capillaries increased, especially in the large intestine. With sequential intoxication, the capillaries were expanded: their diameter was $12.5 \pm 0.9 \mu\text{m}$ in the proximal section - on average $12.8 \pm 0.4 \mu\text{m}$ - and in the distal $13.1 \pm 0.9 \mu\text{m}$ (8.4 ± 0.4 in control). Simultaneously with the increase in the diameter of the capillaries, their lumen expanded, which amounted to 6.0 ± 0.1 , 7.2 ± 0.1 , and $8.0 \pm 0.2 \mu\text{m}$, respectively (4.7 ± 0.3 in the control). The expansion of the lumen of the capillaries was accompanied by a decrease in their thickness. The lumen of the postcapillaries was varicose and was $31.1 \pm 0.4 \mu\text{m}$ in the proximal, 35.1 ± 0.3 on average, and 36.3 ± 0.2 in the distal ($P > 0.001$).

Erosions and ulcerations with infiltrated margins were common in the mucosa. At the bottom of the ulcers, tissue detritus and fibrin were found (Fig.). Stroma of most crypts with pronounced edema and infiltration. There are thinned and deformed pronounced subepithelial edema, exfoliating epithelium from the basement membrane. The lumen of the crypts is enlarged and tortuous, containing microorganisms and mucus. The crypt stroma is densely infiltrated with lymphohistiocytic elements (pic.). After 30-60 days, destructive-atrophic changes continued to progress. The microvessels of the seromuscular membrane markedly decreased in diameter, in some places there are avascular zones



and extravasations.

30 days after acute pesticide inoculation.

Congestive plethora is observed in the ordinal venous vessels of the submucosa. The mucosa contains most of the vessels.

Spasmodically narrowed; avascular zones and blindly ending capillaries are noted, the density of vessels is reduced.



The villi are deformed, shortened, their stroma is infiltrated, the border epithelium is flattened. The crypts are shortened, the gaps of most of them are widened. The stroma is densely infiltrated with lymphohistiocytic elements (pic. 2).

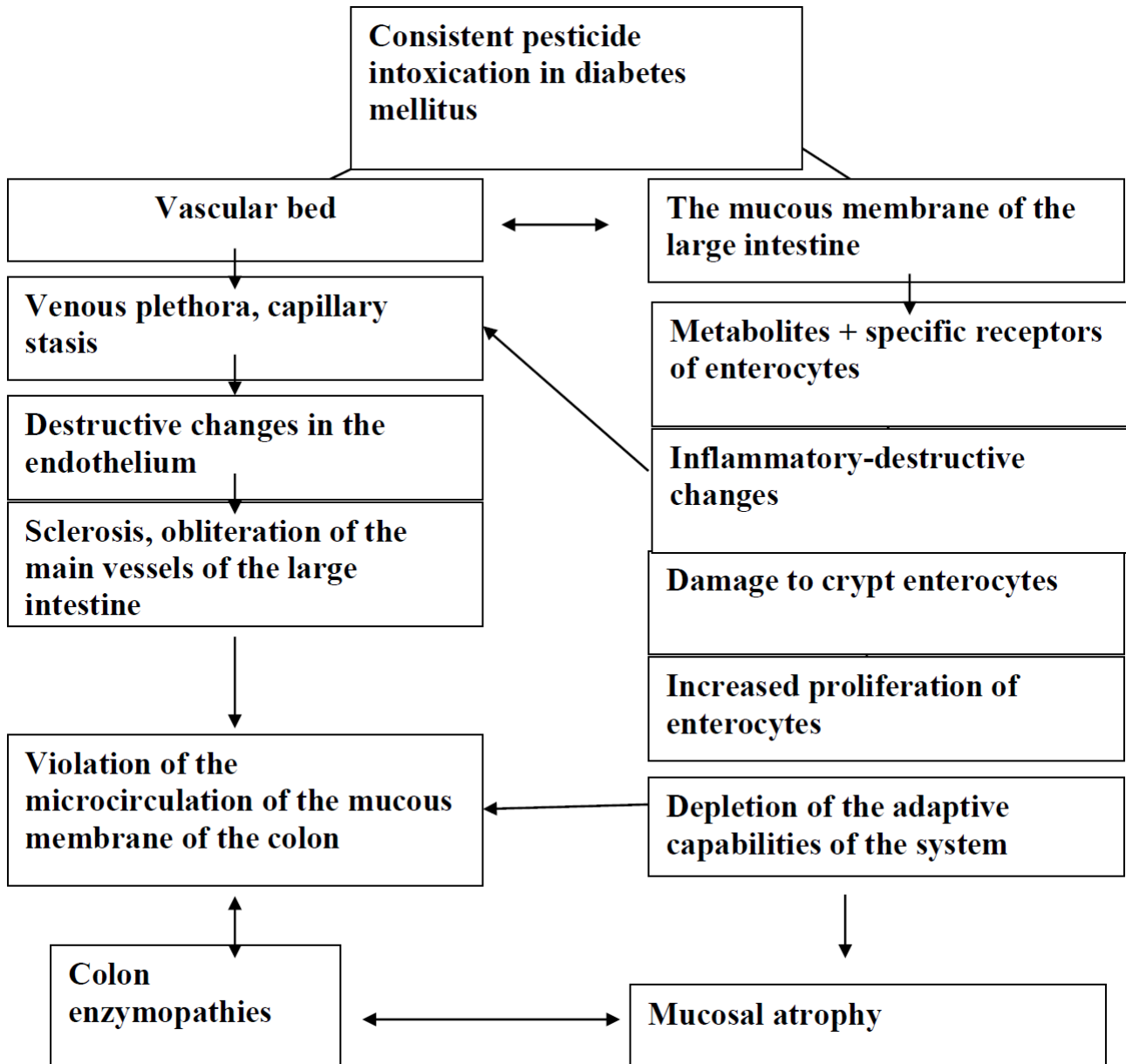
Coarseness of collagen fibers is observed in the submucosa and seromuscular membrane. Atrophic changes in muscle fibers are aggravated. It should be emphasized that such phenomena intensify in subsequent periods. Often there are ulcerations of the mucous membrane, atrophied areas, microerosion with the imposition of tissue detritus. There is an increase in the content of short and bare villi (pic.).

After 90 days, few and avascular zones are observed in the serous-muscular membrane, blindly ending in capillaries. The walls of postcapillaries are varicose. In

some places in the lumen of microvessels, erythrocytes stick together in the form of "coin columns". Often there are point extravasates. The vessels of the submucosal vascular plexus are noticeably narrowed and tortuous. In the mucous membrane, spasmodic vessels and point extravasates are detected, avascular zones are preserved.

The precapillaries and capillaries of the vascular networks are tortuous, in some places they end blindly. A similar picture is observed in atrophied zones. In cells where the epithelial layer is detached from the stroma, there is no capillary network. Postcapillaries are varicose-dilated.

Destructive and atrophic changes are observed in the mucous membrane of all studied sections of the large intestine.



Pathogenetic mechanisms of damage to the large intestine during sequential intoxication with pesticides.

The number of villi noticeably decreases, they are thinned and shortened. The number of capillaries in the stroma decreases. Fibrosis is pronounced, enterocytes are reduced in size. Atrophy develops in the seromuscular membrane.

CONCLUSIONS:

Thus, already in the first days after sequential inoculation, pronounced and degenerative changes in the microvasculature of the colon were observed: swelling, intermuscular infiltration, atrophic changes in

tissue elements, especially in the mucous membrane of the crypts of all layers of the intestinal wall. Microvessels also changed: thinning of precapillaries and capillaries, appearance of extravasates. Such phenomena lead to atrophy of tissue structures (especially the mucous membrane).

Consequently, the consistent poisoning of animals with pesticides "Neoron" and "Sumi-alpha" has a negative impact on the morpho-functional state of the large intestine.

Thus, with sequential intoxication, the severity of the condition is determined by the severity of morphological changes in the mucous membrane of the colon and associated metabolic disorders.



Literature data and our studies show that the morphological changes in the colon mucosa as a whole did not differ from those in the acute period of the disease. With sequential intoxication, blood filling and an increase in the diameter of microvessels of the colon mucosa are noted. Mucosal precapillaries are located eccentrically, which also increases the number of atrophied villi. As a result, a vicious circle is formed between atrophy of the mucous membrane, intoxication, microcirculation disorders, metabolic disorders in the body, decreased digestion, and malabsorption.

Morphological indicators allow you to determine the period of severity of intoxication, but the main feature is morphological data.

Changes in the colonic mucosa that we revealed during a morphological study in rats with sequential intoxication indicate the need for further long-term pathogenetic substantiated therapy.

REFERENCES.

1. Abdulaeva, S.O. Morphological characteristics of the colon mucosa and microbiota in BALB/C mice during adaptation to cold exposure / S.O. Abdulaeva // Morphological sheets. - 2011. - No. 2. - P.9-13.
2. Akimova, T.A. Ecology. Nature - Man - Technique / T.A. Akimova, A.P. Kuzmin, V.V. Haskin. - M.: Unity-dana, 2001. - 343 p.
3. Argyubaeva A.T., Toychuev R.M. Microecology of the human intestine in contact with pesticides (pesticides), its violations and correction with the help of probiotic preparations, preservation and treatment of the altered biocenosis of the intestinal tract // Health of the population and habitat, 2011. No. 7. P. 41-45. Barannikov V.D. Distribution of priority pollutants of the agrosphere in the organs and tissues of farm animals // Veterinary Pathology, 2005. No. 1. P. 81-84. 3. Baryshev Yu.A., Episkoposyan V.E. Environmental protection and human ecological safety // Competence, 2007. No. 1. P. 37-41.
4. Labor safety in the application of pesticides in agriculture / A.V. Initskaya [et al.] // Life safety. - 2006. - No. 1. - S. 17-23.
5. Belyaev, S.A. Influence of intraportal infusions of mexidol on the functional state of the liver and regional circulation in obstructive cholestasis / S.A. Belyaev, A.N. Belyaev, S.A. Kozlov // Regional blood circulation and microcirculation. - 2011. - V. 10, No. 3. - S. 89-93. Bivalkevich, I.V. Morphological changes in liver tissue in experimental dyslipidemia / I.V. Bivalkevich, Yu.K. Karaman // Bul. SO RAMN. - 2010. - V. 30, No. 1. - S. 48-52. Boguslavskaya, N.V. Negative consequences of the use of pesticides / N.V. Boguslavskaya // Environmental safety in the agro-industrial complex. - 2010. - No. 3. - S. 731.
6. Bryzgunova S.S. Evaluation of the toxicological effect of pesticides on the human body // Successes of modern natural science, 2011. No. 8. P. 95-96.
7. Influence of pectin on the morphological structure of the rat small intestine epithelium under lead intoxication / L.V. Kuzmicheva [et al.] // Morfologicheskie Vedomosti. - 2010. - No. 1. - S. 46-48.
8. Golosova, A.V. Genotoxic effects of pesticides: deltamethrin (decis) and metsulfuronmethyl (magnum) / A.V. Golosova, I.V. Pak, T.Yu. Kuznetsova // Vestn. ecology, forest science and landscape science. - 2010. - No. 10. - S. 101-107. Gorbatov, V.S. Structure and forms of information about the pesticide / V.S. Gorbatov, T.V. Kononova // Niva of the Volga region. - 2011. - No. 1. - S. 17-21.
9. State catalog of pesticides and agrochemicals permitted for use on the territory of the Russian Federation (as of July 2011): Ref. ed. - M.: Ministry of Agriculture of Russia, 2011. - 936 p.
10. State catalog of pesticides and agrochemicals permitted for use on the territory of the Russian Federation (as of August 2012) [Electronic resource]. - Access mode: <http://law7.ru/russia/government1s/u422.htm>, free.
11. State catalog of pesticides and agrochemicals permitted for use on the territory of the Russian Federation for 2013. - M.: Ministry of Agriculture of Russia, 2013. Zakharenko, V.A. Interested in pesticides / V.A. Zakharenko // Protection and quarantine of plants. - 2012. - No. 1. - S. 11-12.
12. Kvashnin Yu.A. State ecological expertise and assessment of the impact of pesticides and agrochemicals on the environment / Yu.A. Kvashnin // Protection and quarantine of plants. - 2011. - No. 4. - S. 65.
13. Ovsyannikov N.V., Lyapin V.A., Avdeev S.N. Environmental pollution and the incidence of bronchial asthma in the adult population of a large industrial city // Kazan Medical Journal,



2011. T. 92. No. 4. P. 577-581. Effects of hyperglycemia on gastric acid secretion during the gastric phase of digestion. / W. F. Lam, A. A. Masclee, E. S. Muller and C. B. Lamers // *AJP - Gastrointestinal and Liver Physiology*. - 1997. - Vol 272. - Issue 5. - P. 1116-1121.
14. Mostafalou S., Abdollahi M. Concerns of environmental persistence of pesticides and human chronic diseases // *Clinical and Experimental Pharmacology and Physiology*, 2012. № 2. P. 3.
15. Anorboyevich, N. D., Doniyorovna, A. I., Khayrullayevich, P. K., Ravshanovna, S. D., & Sobirovich, M. R. (2022). Modern diagnosis of nephroblastoma in children.
16. Abdusolievich, K. N., Jahongirovich, U. R., Khairullaevich, P. K., Ravshanovna, S. D., & Ubaydullaevich, K. A. (2023). Dynamics Of Development of The Microvasculature and Tissue Structures of The Large Intestine in Case of Sequential Pesticide Poisoning. *Journal of Survey in Fisheries Sciences*, 352-361.
17. Ravshanovna, S. D., Djakhangirovich, U. R., Khusanovna, A. F., Khayrullayevich, P. K., Ruzibayevich, T. I., & Khosilovna, U. Z. (2023). Morphological Assessment of Changes in the Macro-and Microvascular System of Lung Tissue in Diabetes Mellitus.
18. Ravshanovna, S. D., Djaxangirovich, U. R., Xayrullayevich, A. F. K. P. X., & Ismatullayevna, M. S. (2023). The role of immunohistochemistry in pancreatic endothelium in diabetes mellitus.