



CHANGES IN THE MORPHOLOGICAL AND MORPHOMETRIC PARAMETERS OF THE GASTRIC WALL IN POLYPHARMACY WITH ANTI-INFLAMMATORY DRUGS

Tashmamatov B. N., DJumanova N.E.

Department of Human Anatomy, Samarkand State Medical University

Article history:

Received: March 20th 2023
Accepted: April 22nd 2023
Published: May 24th 2023

Abstract:

Polypharmacy is becoming more common due to an aging population, an increase in the number of people with multiple diseases, and more disease recommendations. Although treating patients with complex medical problems with the right medications can improve clinical outcomes, quality of life, and life expectancy, polypharmacy is also associated with an increased risk of adverse drug reactions, some of which are serious enough to lead to hospitalization and even death. Therefore, it is critical to have systems in place to ensure that medications are only started when indicated, that patients are fully informed of the benefits and potential complications of treatment, and that patients are regularly reviewed to ensure compliance with their medication regimen

Keywords: Polypharmacy, multiple diseases, clinical outcomes, digestive system, lymphoid tissues.

INTRODUCTION. The digestive system plays an important role in the interaction of the body with the external environment. Since the mucous membrane of the alimentary canal is affected by various substances contained in food, it is understandable that the mucous membrane and submucosal base, which are immune organs, have their own lymphoid structures.

The mucous membrane of the organs of the digestive system is considered a barrier system that blocks the entry of various agents into the body from the outside, and on the other hand, it participates in the exchange processes of the external and internal environment of the body. Due to its direct proximity to microbiota and food, it is constantly exposed to normal as well as potentially dangerous antigens.

Diseases of the gastrointestinal system occupy one of the highest places in terms of morbidity of the population. Epidemiological studies conducted on gastroscopy and morphological evaluation of the gastric mucosa revealed that more than half of the population suffers from chronic gastritis.

Immunocompetent tissues of the digestive system are called "lymphoid tissues". Lymphocyte recirculation and the immune response cover the mucosa of the entire gastrointestinal tract.

Circulating lymphocytes are involved in the recovery of the cellular composition of irradiated lymph nodes.

The arrival of a significant amount of natural flora after birth induces its immunological responses, namely the expansion of the intraepithelial lymphocyte population and the expansion of the distribution of cells in the crypts.

The further development of knowledge about the lymphatic system cannot be done without taking into account the processes that occur around the lymphatic capillaries and in the interstitium.

The morpho-functional state of the organs of the digestive system changes under the influence of various factors of the external environment. A study of the status of fat cells located in the alimentary canal during space flights showed that the number of fat cells decreased against the background of increased expression of chymase in the stomach in the antigravity state of the organism.

Artificial feeding leads to an increase in large neurons of intermuscular ganglia of the stomach and a decrease in neuron ganglions of medium-sized nerve cells (21%).

Injuries of the muscle layer of the stomach wall in the form of cutting, crushing and thermocoagulation lead to increased proliferative activity of myocytes near the gastric ulcer.

The effect of zirk leaf extract on the surface of gastric ulcer resulted in a significant decrease in ulcer healing times. In patients with arterial hypertension, the healing time of gastric ulcer is prolonged.

The purpose of the study. Study of morphological and morphometric parameters of gastric mucosa wall in polypharmacy with anti-inflammatory drugs.

Tasks of the research:

1. To study changes in the morphological and morphological parameters of the stomach of 5-month-old purebred rats in the norm, as well as when anti-inflammatory drugs are used individually.



2. To determine the morphological and morphometric parameters of the gastric wall of 5-month-old white rats when two, three, four and five types of anti-inflammatory drugs are used in different combinations, and to determine the change in the morphometric and morphometric parameters of the gastric wall.

3. To study the morphometric and iorphometric changes caused by the simultaneous use of two, three, four and five types of anti-inflammatory drugs in 5-month-old purebred rats.

Recent years have also seen the development of smartphone applications such as "My Medicine Passport" to improve communication between patients and health care providers, improve people's understanding of their condition and treatment, and track changes to a patient's medication.

Polypharmacy is the simultaneous use of several drugs by one patient. As the population ages in the developed world, particularly the UK, the number of people with chronic diseases is increasing, and there is increasing pressure on doctors to adhere to evidence-based guidelines for the management of chronic diseases.

Despite the fact that many studies are conducted in polypragmasy, information about the stomach, which is the central organ of the alimentary canal, is very scarce in the literature.

MATERIALS AND METHODS OF RESEARCH. The study was conducted on a total of 180 5-month-old adult white rats. According to the purpose of the study, all laboratory animals were divided into 5 groups. 5 different types of anti-inflammatory drugs were used in polypharmacy in different combinations.

The histological material obtained from the cardiac, bottom, body and pyloric parts of the stomach of the experimental white male rats served as the subject of the study.

Research methods.

- staining micropreparations with hematoxylin-eosin
- staining of micropreparations by Van-Gieson methods
- Determination by variational statistics method using Strelkov tables

RESEARCH RESULTS AND DISCUSSION.The stomach of non-white rats lies mainly under the liver. A large curvature of the stomach emerges from under its sharp caudal edge. It is on the left side and slightly caudal to the lesser curvature, dorsal to the gastric

fundus and slightly cranial to the pyloric portion. Thus, the stomach of the white rat is located almost transversely (between the sagittal and transverse planes).

The entry of the stomach into the duodenum (pyloric) and the cranial part of the duodenum join immediately to the right of the midline, at an open ventrocaudal angle. Below it (caudal) are 12 loops of the duodenum and (ventral to these loops) the terminal part of the acute angle of the ileum, and even more ventrocaudal - the cecum. Dorsocaudal (behind) the pyloric part and body of the stomach are the transverse colon, the body and tail of the pancreas. From the large curvature of the body of the organ and from the bottom of the stomach to the left and dorsally, the spleen is located.

The following indicators were determined when the topographic-anatomical and skeletoscopic data of the white rat's stomach were studied. In non-laboratory white rats, the upper or upper back wall of the stomach touches the jejunum and ileal loops on the right side, and the left adrenal gland and the left kidney on the left side. Stomach covers the upper 2/3 of the lower surface of the adrenal gland of the left kidney and closes the upper end of the left kidney, that is, the front end. The left side of the stomach is rounded, it is located mainly under the diaphragm, and on the left side it is located touching the spleen. The right side of the stomach narrows and joins from the last part to the beginning of the duodenum. For the first time, it was found that polypharmacy with anti-inflammatory drugs in 5 combinations had different negative effects on the mucosa and submucosa, which is the structural structure of the stomach wall of white male rats;

Structural changes in the organs of the digestive system have been proven to cause profound disturbances in the processes of growth and formation of the mucous membrane of the stomach and its glandular tissue, submucosa base, which is found to be accompanied by a decrease in the total thickness of the stomach wall;

When using more than 3 types of anti-inflammatory drugs at the same time, the negative effects of polypharmacy increase significantly. The rate of formation of the structural and functional zones of the stomach wall, the activity of cells in the mucous membrane, the change in the shape of the lymphocytes located at the base of the mucosa, and the decrease in the morphological parameters were analyzed;

Using the methods of modern morphological research (organometric, histological, histomorphometric, statistical), new information was obtained directly about the morphological and morphometric parameters of the stomach wall. Changes identified at the tissue, cellular and intercellular levels are characterized by hypotrophic and hypoplastic changes in the structures of the gastric wall of the white male rat.

There are several lines from the abdominal organs of white rats to the stomach, and they are as follows: Stomach-splenic line: - from the spleen to the great curvature of the stomach; Diaphragm-stomach line: - from the diaphragm to the left half of the greater curvature of the stomach; Liver-stomach section: - from the area of the liver gate to the small curvature of the stomach; Gastrointestinal tract: - starts from the great curvature of the stomach and continues to the transverse colon.

Five-month-old purebred laboratory rats have fully formed stomachs. When the five-month-old rats in the experiment were examined macroscopically, the following data were obtained:

The body weight of five-month-old laboratory animals varied from 189-258 g, and the average was 244.6 ± 6.3 g. The total length of the white rat stomach in the control group was 33-35 mm, with an average of 34.62 ± 0.18 mm. The width of the member varied from 13 to 15 mm and averaged 13.81 ± 0.18 mm. The thickness of the studied organ varied from 12 to 15 mm, and the average was 13.69 ± 0.32 mm. The length of the large curvature is around 37 - 38 mm, on average 37.43 ± 0.10 mm. The length of the small curvature was 14 - 15 mm the average was equal to 14.65 ± 0.10 mm.

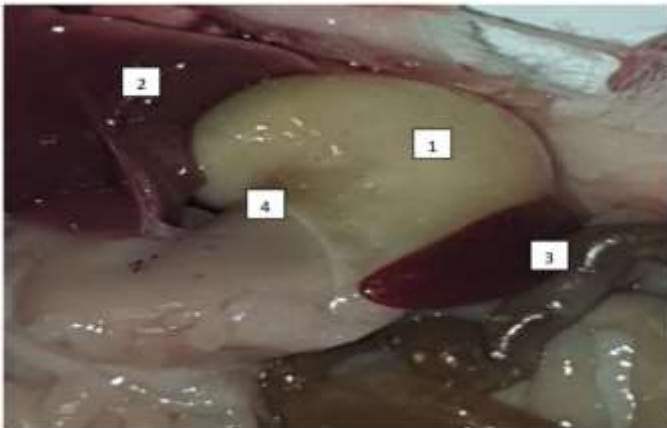


Figure 1 and 2. Anatomy of the stomach of a 5-month-old purebred rat.

The following data were collected when examining the microscopic findings of the control group. According to this, the height of the mucous layer of the gastric wall of white rats in the period of five months varies from 433.9 to 524.3 μm in the area of the esophagus to the stomach (cardial part), and the average is 473.9 ± 8.32 μm ; (Figure 1). The height of the mucosa at the bottom of the organ varied from 442.1 to 529.3 μm , and the average was 509.4 ± 8.02 μm . The height of this layer in the body area of the stomach is 448.1-546.8 μm , on average 511.8 ± 9.08 μm ; the height of the mucous layer in the pyloric part was 476.5 μm from 381.4 μm , and the average index was 427.4 ± 8.75 μm (Fig.2).

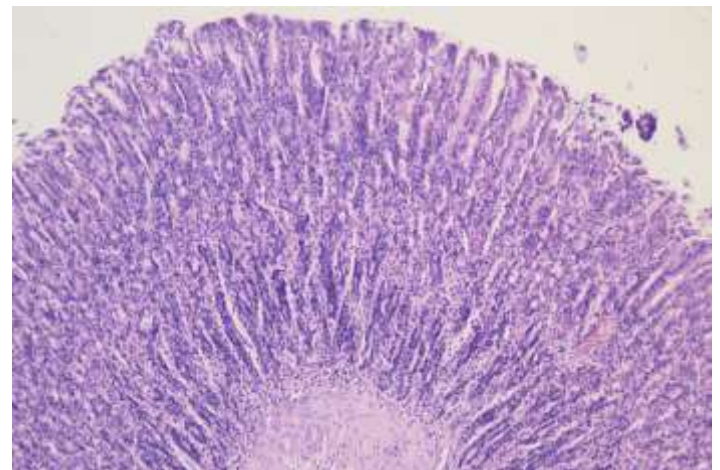


Figure 3. The structure of the cardiac part of the stomach of 5-month-old white rats. 1 – mucosal layer, 2 – submucosa base, 3 – muscle layer, 4 – bundle of collagen fibers, 5 – cavity between folds. Van – painted according to Gizon.Ok.10hob.4.0

The mucous layer on the stomach wall of purebred rats belonging to this group is covered with a multi-layered epithelium, the epithelial layer of which has three rows: - basal cells; - it can be seen that it is composed of round cells and oval cells. The presence of the above-mentioned cells is characterized by the fact that they are not very large, close together and have a nucleus in the center of the cell. The composition of the cell located in the middle and upper rows is oval, and it can be seen that the larger cell nuclei are located eccentrically. There are granules with secretory properties located in the apical part of these cells.

The height of the fold of the cardiac part of the stomach wall was 425.3-505.8 μm , and its average was 456.5 ± 7.41 μm . In the bottom area, this indicator ranges from 430.3-518.1 μm , with an average of



473.0±8.08 µm. The height of the fold of the body part of the stomach wall varied from 438.4-538.5 µm, and on average it was 492.5±9.2 µm. And in the area of transition to the duodenum (pyloric part), this indicator was 372.3-468.9 µm. The height of the cavity between the folds of the mucous membrane, which is one of the components of the stomach wall, was 384.3-462.1 µm in the cardiac part, and its average value was 411.5±7.16 µm. It can be seen that it varies from 388.4 to 471.8 µm in the bottom area, and our average indicator is 422.1±7.67 µm. When the body part of the stomach wall was studied, this indicator was 392.6-491.4 µm, the average was 448.7±9.1 µm. In the pyloric part of the organ, the height of the groove between the studied folds was 331.2-421.8 µm, and its average was 365.9±8.34 µm. The thickness of the submucosa base under the mucous layer of the stomach wall in the cardiac area of the organ varied from 38.6 to 47.3 µm, and the average was 42.7±0.8 µm. The thickness of the submucosal base at the bottom of the organ varied from 39.4 to 45.8 µm, and the average was 43.2±0.59 µm. The thickness of the submucosa base in the body part of the stomach wall is 40.3-48.1 µm, on average 43.6±0.72 µm.(Figure 3)

CONCLUSION. Different levels of morphological changes occur under the influence of different amounts of drugs. According to the obtained data, the overall thickness of the stomach wall significantly decreased in groups IV-V due to the decrease in the size of the gastric mucosa and the mucosal base after the effect of drugs. These changes were 1.60% in the cardiac part, 3.27% in the gastric fundus, 3.33% in the body, and 3.65% in the pyloric part of laboratory animals of group IV, and 2.21% in the cardiac part of organ in laboratory animals of group V. %, changed to 3.89% in the base, 3.0% in the body of the stomach and 5.2% in the pyloric part.

2. When the adverse effects of polypharmacy with anti-inflammatory drugs were compared between the rats of the experimental control group and the rest of the groups, when the measurements of all the morphometric parameters obtained were viewed in the increasing order of the group, it was observed that the negative effects significantly increased in accordance with it and parallel to it.

3. The adverse effect of polypharmacy of anti-inflammatory drugs in the experimental group of rats in the stomach wall, mucosal base and glandular tissue was corrected in the V-group compared to the I-control group. In this case, in the cardiac part of the organ wall of group V, the height of the mucous layer

of the gastric wall is 8.4%, the mucous base is 10.5%, and the glandular tissue is 37.0%, the mucous membrane is 7.60%, the mucosa is 17.8% in the bottom of the stomach. , and in the gland tissue by 29.7%, the height of the mucous membrane in the organ body by 6.52%, the base of the mucosa by 16.7% and in the gland tissue by 34.4%, the height of the mucous membrane in the pyloric area of the stomach by 6.2%, the mucosa it was found that it did not decrease by 15.9% in the base and by 32.2% in the gland tissue.

REFERANCES

1. Vasilieva E.A. Clinical biochemistry of agricultural animals.// M: Ros-selkhoz publishing house, 2014 - 257p.
2. Weber F.E. Transport of ions in prev. stomachs of ruminants.// - Syktyvkar, 2015.- p. 40
3. Weber A.E. The exchange of mineral ions in the multi-chamber stomach of cows when fed with complete feed mixtures// Metabolism of ruminants// - Syktyvkar, 2017 - p. 40-48.
4. Weber A.E. The dependence of the transport of mineral ions in the small intestine of sheep on their ratio in the diet // Assimilation of nutrients in ruminants - Syktyvkar, 2017-p.61-69.
5. Venediktov A.M. Trace elements for highly productive cows // Animal husbandry - 2015-№1.p.77-78.
6. Venchikov A.I. Physiologically active amounts of trace elements as a biotic factor. //Riga, 2019, - p.571-575.
7. Nazarova F.Sh., Matkarimova G.M. Morpho - physiological and biochemical adaptations of helminthes.
8. Nazarov Sh.N., Rish, M.A., Shukurov D. Use of chemical analysis of wool in large-scale biogeochemical zoning and differential use of trace elements in animal husbandry.//№7.p.32-34.
9. Nazarov Sh.N. Polarographic determination of zinc in plant material. Ed. "Fan", Tashkent, 2009, p.179.
10. Rish. M.A., Nazarov Sh.N. The content of some trace elements in the wool of karakul sheep of various colors. //M.2013.No.9.p.49-54.
11. Nazarova F.Sh., Khudoyberdieva G., Dzhumanova N.E. Biochemical



- comparative analysis of the ecological composition of phytonematodes.
12. Nazarova F. Sh., Dzhumanova N. E. Use of bentonite from the Azkamar deposit for balancing mineral nutrition // Academic research in the field of pedagogical sciences. - 2021. - Issue. 2. - No. 9. - C. 672-679.
 13. Nazarova F.S., Dzhumanova N.E. Hair and coat as indicators of environmental pollution by technogenic and geochemical sources // Thematic Journal of Microbiology. - 2022. - Issue. 6. - No. 1.
 14. Nazarova F.S., Dzhumanova N.E., Tashmamatov B.N., Sh. O. Korzhavov. Ecological grouping of phytonematodes. Problems of biology and medicine. - 2020. No. 6. Volume 124. - C. 258-261.
 15. Nazarova F.Sh., Dzhumanova N.E. Biological role of microelements and their content in epidermal formations. Economy and society.1-2 (92).2022. p. 94-103
 16. Toshmamatov B.N. and coavt. Macroscopic structure of the ileocecal flap in rabbits // International Scientific and Practical Conference "World Science. - POCT, 2017. - C. 5. - No. 5. - C. 58-59.
 17. Toshmamatov B.N. and coavt. Macroscopic structure of the ileocecal foramen of rats and rabbits in postnatal ontogenesis // International Scientific and Practical Conference "World Science. - POCT, 2018. - No. 3. - No. 5. - C. 53-54.
 18. Toshmamatov B.N. Morphological changes in the stomach with polypharmacy Home page of Science LLC Received 04/04/2021 Received 04/20/2021
 19. Toshmamatov B.N., Teshaeв Sh.J., Khudoyberdiev D.K. Consequences of polypharmacy with anti-inflammatory drugs on the morphology of the stomach wall Problems of Biology and Medicine 2022, No. 1 (134) C.157-164
 20. Toshmamatov B.N., Teshaeв Sh. J., Khudoyberdiev D.K., Morphological structure of the gastric mucosa in polypharmacy with anti-inflammatory drugs 0, January 2022, pages 32-38
 21. Toshmamatov B.N., Teshaeв Sh. J. Changes in the morphological structure of the mucous membrane in polypharmacy. (2021). American Journal of Medical Sciences and Pharmaceutical Research, 3 (08), 51–57.
 22. Toshmamatov B.N., Teshaeв Sh.J., Khudoyberdiev D.K. Changes in the morphological parameters of the gastric mucosa and the base of the gastric mucosa of squirrels with polypharmacy. Problems of biology and medicine 6. 2022, №3 (136) C.190 -195
 23. Toshmamatov B.N., Teshaeв Sh.Zh., B.N. Histological changes in the stomach during treatment with nosteroid drugs Problems of biology and medicine 2 (34) 2021 / C.260-264
 24. Toshmamatov B.N. Morphometric parameters of the gastric mucosa in polypharmacy on anti-inflammatory drugs 9 (47) 2022. A new day in medicine. C.187-195
 25. Toshmamatov BN et al. Macroscopic structure of the ileocecal valve in rabbits. //International Scientific and Practical Conference World science. - ROST, 2017. - Vol. 5. - No. 5. - S. 58-59.
 26. Toshmamatov B. N. et al. Macroscopic structure of the ileocecal orifice in rabbits and rats in postnatal ontogenesis //International Scientific and Practical Conference World science. - ROST, 2018. - Vol. 3. - No. 5. - S. 53-54.
 27. Khudaiberdieva G. A., Nazarova F. Sh., Dzhumanova N. E. Comparative analysis of the ecological composition of plant nematodes // Forum of Young Scientists. – 2021. – no. 4. - S. 381-385.
 28. Dzhumanova NE, Nazarova FS PROBABLE NEGATIVE IMPACT OF GENETICALLY MODIFIED PRODUCTS ON HUMAN HEALTH // Thematics Journal of Botany. - 2022. - T. 6. - No. 1.
 29. Nazarova FS, Dzhumanova NE HAIR AND WOOL AS INDICATORS OF ENVIRONMENTAL POLLUTION BY MAN-MADE AND GEOCHEMICAL SOURCES // Thematics Journal of Microbiology. - 2022. - T. 6. - No. 1.
 30. Sharipovna NF et al. BIOLOGICAL ROLE OF MICROELEMENTS AND THEIR CONTENT IN EPIDERMAL FORMATIONS // European Journal of Molecular and Clinical Medicine. - 2021. - T. 8. - No. 2. - S. 1675-1687.