



THE ROLE AND SIGNIFICANCE OF THE KI67 PROLIFERATION MARKER IN DIFFERENTIATED THYROID CARCINOMA

**M.S. Khudayorov¹, O.B. Abdurakhmonov², D.A. Nishanov³, A.A. Madaliyev⁴
U.A. Soatov⁵**

1. Tashkent medical university, assistant,
2. Akfa Medline Clinic, D.M. Sc.,
3. Republican Center of Pathological Anatomy, D.M. Sc., professor,
4. Republican Specialized Scientific and Practical Medical Center of Oncology and Radiology,
5. Termez Branch of Tashkent medical university, assistant.

Article history:	Abstract:
Received: August 26 th 2025 Accepted: September 22 th 2025	This article presents data from literature sources regarding the epidemiology, diagnosis, and treatment methods of differentiated thyroid carcinoma. The Ki67 proliferation marker was evaluated in tissue samples from 20 patients with differentiated thyroid carcinoma. The results of the immunohistochemical analysis were assessed based on the intensity of the positive reaction — mild, moderate, and high. The study describes the percentage distribution of patients showing different levels of Ki67 expression.

Keywords: Differentiated thyroid carcinoma, immunohistochemistry, Ki67, proliferative activity

ҚАЛҚОНСИМОН БЕЗ ДИФФЕРЕНЦИАЛЛАШГАН САРАТОНИДА КІ67 ПРОЛИФЕРАЦИЯ МАРКЕРИНИНГ РОЛИ ВА АҲАМИЯТИ.

М.С.ХУДАЁРОВ¹, О.Б.АБДУРАХМОНОВ², Д.А.НИШАНОВ³, А.А.МАДАЛИЕВ⁴, У.А.СОАТОВ⁵.

1. Тошкет Давлат тиббиёт университети, ассистент,
2. Акфа медлайн клиникаси, т.ф.д.,
3. Республика патологик анатомия маркази, т.ф.д., профессор.
4. Республика ихтисослаштирилган онкология ва радиология илмий амалий тиббиёт маркази,
5. Тошкет Давлат тиббиёт университети Термиз филиали, ассистент.

Аннотация. Мақолада қалқонсимон без дифференциаллашган саратони эпидемиологияси, таххислаш ва даволаш усуллари бўйича адабиёт манбаларидан олинган маълумотлар келтирилган. Мақолада қалқонсимон без дифференциаллашган саратонида Ki67 пролиферация маркери текширилган 20 нафар бемор тахлилларида натижалар энгил, ўрта ва оғир даражали позитив реакция натижалари орқали баҳоланган. Беморларнинг неччи фоизида энгил даражали позитив реакция, ўрта даражали позитив реакция ва юқори позитив реакция кузатилганлиги тавсифланган.

Калит сўзлар: дифференциаллашган саратони, иммуногистохимия, Ki67, пролифератив фаоллик.

Each year, approximately 122,000 new cases of thyroid cancer are recorded worldwide, accounting for about 1% of all malignant tumors. In different regions, the incidence per 100,000 population ranges from 1.9 to 19.4 among women and from 0.8 to 5.0 among men [1]. Thyroid cancer is mainly classified into the following histological variants:

1. Differentiated carcinoma, which is subdivided into papillary and follicular carcinomas;
2. Anaplastic (undifferentiated) carcinoma;
3. Medullary carcinoma;
4. Hürthle cell carcinoma;
5. Thyroid lymphoma.

Thyroid cancer predominantly develops from nodular lesions and may be observed at any age. The likelihood of malignancy arising from nodular goiter increases with advancing age. Only 2–5% of nodular lesions are malignant, and the majority of malignant cases are represented by differentiated carcinomas [2, 3, 4].

Highly differentiated thyroid carcinoma develops from the epithelium of follicular cells and is subdivided into papillary and follicular types.

Anaplastic and poorly differentiated forms are mainly observed in elderly patients and usually arise after long-standing differentiated carcinoma as a result of mutational changes [5, 6].

Therefore, proliferation markers play an important role in determining the biological behavior of these tumors, particularly the Ki-67 index. At the molecular level, specific mutations associated with thyroid cancer (such as Ki-67, Bcl-2, p53, CD34, and others) have been identified, indicating their potential sensitivity to targeted therapy.

The primary treatment approach is radical surgery followed by radioiodine therapy, which, depending on clinical necessity, may be supplemented with radiotherapy or chemotherapy (targeted therapy and immunotherapy).

For our study, 20 patients with papillary thyroid carcinoma were selected. In all patients, the obtained results were evaluated as a percentage, reflecting the

proliferative activity of tumor cells based on the Ki-67 marker. The proportion of Ki-67-positive tumor cells (Ki-67 labeling index) is often associated with the clinical course of malignant disease. The results were assessed according to mild, moderate, and severe degrees of positive reaction. In all patients, the obtained results were evaluated as a percentage, reflecting the proliferative activity of tumor cells based on the Ki-67 marker. The results were assessed according to mild, moderate, and severe degrees of positive reaction. Among the 20 patients, 17 (85%) demonstrated a high-grade positive reaction, while 3 (15%) showed a moderate positive reaction. No cases with low positive reaction were observed.

Figure 3.

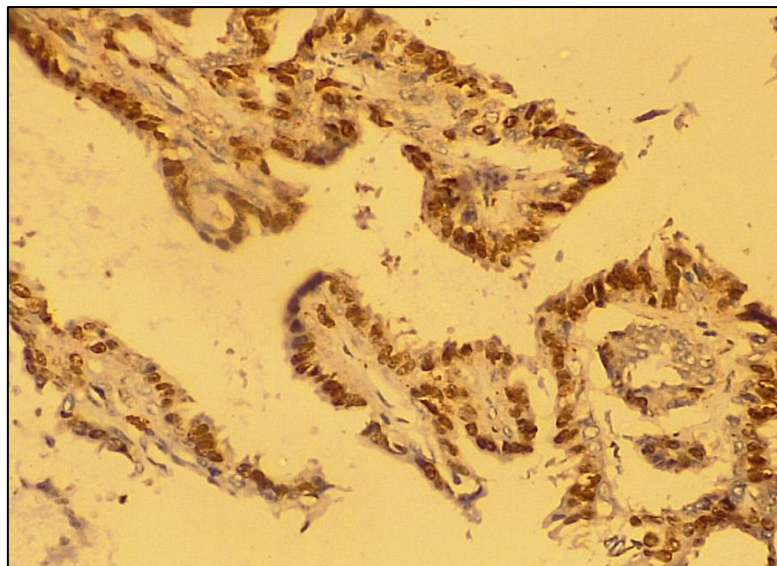


Figure 3. High-grade positive reaction in papillary malignant tumors of the thyroid gland. IHC – DAB chromogen. Obj 10x, Oc 40x.

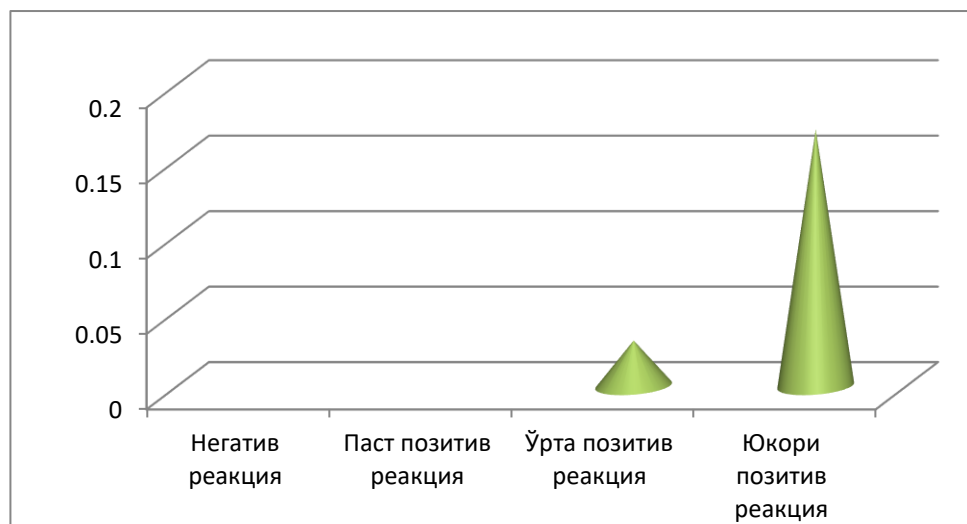
Papillary malignant tumors of the thyroid gland: proliferative activity level of the Ki-67 reagent presented in tabular form, No. 20.

Table 4.

Nº	NºDegree	Patients
1	Less than 10% — low proliferative activity	0
2	10–20% — moderate activity	3
3	> 20% — high proliferative activity**	17

Papillary malignant tumors of the thyroid gland: proliferative activity level of the Ki-67 reagent presented in a chart/table, No. 20.

Table 5.



CONCLUSION

Immunohistochemical (IHC) studies are conducted to analyze various biological processes. This investigation is important for identifying molecular structures within cells, studying cell localization, examining the spread or histogenesis of tumors, monitoring events during the development of precancerous conditions, determining prognostic indicators of diseases, identifying tumor stages and appropriate treatment strategies, controlling dynamic observation and treatment processes, and identifying risk groups for potential tumor development.

Based on the results of the conducted study, it was found that papillary thyroid carcinoma exhibited predominantly moderate to high positive reactions with Ki-67 reagents. Therefore, it can be concluded that papillary thyroid carcinoma demonstrates a relatively aggressive clinical course.

REFERENCES

1. Pathology and genetics of tumours of endocrine organs / ed. by R. A. DeLellis et al.) -Lyon : IARC Press, 2004. - 320 p . : ill. - (World Health Organization classification of tumours)).
2. Дедов И.И., Мельниченко Г.А., Фадеев В.В., Герасимов Г.А., Гринева Е.Н., Кузнецов

- Н.С., Ванушко В.Э., Бельцевич Д.Г., Свириденко Н.Ю., Трошина Е.А., Петунина Н.А., Мазурина Н.В., Гарбузов П.И.,
3. Румянцев П.О., Ильин А.А., Артемова А.М. Клинические рекомендации РАЭ по диагностике и лечению узлового зоба // Проблемы эндокринологии. 2005. Т. 51. №5. С.40–42.
4. Диагностика и лечение дифференцированного рака щитовидной железы: Национальные клинические рекомендации, принятые на XI Российском онкологическом конгрессе и IV Всероссийском тиреоидологическом конгрессе // Эндокринная хирургия. 2008. № 1 (2). С. 3–5.
5. Hegedüs L. Clinical practice. The thyroid nodule // N Engl J Med. 2004 Oct 21. Vol. 351 (17). P.1764–1771.
6. Kondo T., Ezzat S., Asa S.L. Pathogenetic mechanisms in thyroid follicular-cell neoplasia // Nat Rev Cancer. 2006. Vol. 6 (4). P. 292–306.
- 6 Nikiforova M.N., Nikiforov Y.E. Molecular diagnostics and predictors in thyroid cancer // Thyroid. 2009. Vol. 19 (12). P. 1351–1361.



World Bulletin of Public Health (WBPH)

Available Online at: <https://www.scholarexpress.net>

Volume-53 December 2025

ISSN: 2749-3644