



## RESULTS OF EMERGENCY OSTEOPERFORATION IN ACUTE POSTOPERATIVE SPONDYLODISCITIS

**Tilyakov Aziz Burievich**

Samarkand State Medical Institute, course of traumatology and orthopedics of DKTF, Uzbekistan

**Nazarov Sarboz Parda ugli**

Samarkand State Medical Institute, course of traumatology and orthopedics of DKTF, Uzbekistan

**Umirov Abdullo Sulaimonovich**

Samarkand State Medical Institute, course of traumatology and orthopedics of DKTF, Uzbekistan

### Article history:

**Received:** January 11<sup>th</sup> 2022  
**Accepted:** February 11<sup>th</sup> 2022  
**Published:** March 30<sup>th</sup> 2022

### Abstract:

. A compression fracture of the spine is the most pressing problem of modern vertebrology and orthopaedic surgery. Traumatic injuries resulting in damage to the structural integrity of the thoracolumbar spine can lead to a number of serious health consequences. Only the quickest and most adequate fixation, unloading of the injured segment and the formation of a strong muscular corset give a real chance of full recovery.

**Keywords:** Spondylitis, spondylodiscitis, biopsy, osteoperforation

**INTRODUCTION.** Excessive strain on the spine increases pressure in the interdigital space and leads to compression and a wedge-shaped deformity. The injury is therefore accompanied by very sharp pain in the back, sometimes extending to the abdomen. Shortness of breath, nausea, vomiting, and numbness of the upper and lower extremities may also occur. A haematoma appears at the site of the injury and soft tissue swelling develops. Paresis and paralysis may occur if the integrity of the structures of the spinal cord is compromised. In the pathological forms typical of the elderly, the symptoms of a spinal compression fracture are absent or very mild. Therefore, these injuries are more often detected in the diagnosis of other diseases.

Infective spondylitis accounts for 4-8% of purulent musculoskeletal disorders, with an incidence of 1.0-2.5 new cases per 100000 population. A special form of spondylodiscitis, acute postmanipulative spondylodiscitis, occurs in one in 40-50 patients who have undergone posterior access discectomy for a herniated disc, given that this is the most frequent operation in neurosurgery - this allows us to assess the overall extent of the problem.

There is no unequivocal treatment tactic for spondylodiscitis, due to the characteristics of the clinical course and duration of the disease. For patients with neurological disorders and spinal epidural abscess urgent decompression of nerve structures is unambiguously recommended, and in non-specific spondylitis corresponding to 1-2 degrees of severity according to HomagkL. etal. or type A of the currently most cited tactical classification PolaE. etal. many authors recommend only conservative treatment. First

and foremost, antibiotic therapy is the only treatment, but the peculiarities of the local blood flow in the intervertebral discs (reduction or complete absence of blood flow) do not initially suggest achieving high ("therapeutic") concentrations in the lesion, which can lead to chronicity of the process.

It should be noted that recommendations for emergency surgical treatment of spondylodiscitis usually refer to drainage of the inflammation, one of the pathogenetic components of which is high intraosseous pressure, characteristic of any acute osteomyelitic process. We were unable to find any publications dealing with targeted treatment of this component in acute spondylodiscitis.

Purpose of the study: To study the results of emergency osteoperforation in acute postoperative spondylodiscitis.

Materials and Methods: The case histories of patients treated in the Samarkand Branch of the Republican Scientific and Practical Center for Orthopedics and Traumatology in the Department of Spine Surgery for 2009-2022 were used as the study material. The data of 40 patients were studied and they were divided into 2 groups. Women comprised 57.5% (n=23) and men 42.5% (n=17), ranging in age from 30 to 63 years. All patients underwent discectomy from posterior access, disc curettage, and antibiotic therapy started the day before surgery and lasted 8 days. Postoperative spondylodiscitis persisted for up to 3 months after surgery in the patients studied. Depending on the level of intervention, the patients were distributed as follows: LIII-IV - 7 (17.5%), LIV-V - 20 (50%) and LV-SI - 13 (32.5%). All patients were classified as type A according to NCPSPolaE et al.



The study group consisted of 28 patients with acute spondylomyelitis who were treated according to the method we developed; the comparison group consisted of 12 patients treated conservatively (Table 1).

**Table 1**  
 Characteristics of compared patient groups by gender and level of discectomy abs., (%)

Indicator	Core group, n=28		Comparison group, n=12		χ <sup>2</sup> - test
	abs.	%	abs.	%	
<b>Gender</b>					χ <sup>2</sup> = 0.383 df = 1 p = 0.536
Men	12	44,4	5	41,7	
Women	15	55,6	7	58,3	
<b>Level of discectomy</b>					χ <sup>2</sup> = 3.423 df = 2 p = 0.181
LIII-IV	5	17,9	2	16,7	
LIV-V	14	50	6	50	
LV-SI	9	32,1	4	33,4	

A change in the nature of the pain syndrome, which is usually constant before the operation, is crucial for the diagnosis of the disease, but becomes a painful one some time after the operation. Only 8 patients developed such complaints on the 2nd day after surgery: in the remaining 20 cases the clinical picture developed 2 weeks later. The slightest movement increases the pain, which often causes the patient to take a forced position and not bend the lower extremities (such pain and position differ from pre-operative disc herniation, when positive symptoms of radicular tension are relieved by bending the lower extremities in the knee and hip joints). Typically, an increase in temperature, sedimentation and leucocyte counts in postoperative spondylomyelitis was detected on day 4-6 postoperatively.

The only MRI sign of spondylomyelitis in the early days of the disease is bone marrow swelling. Increasing back pain is caused by increased intraosseous and intradiscal pressure, irritation of the nerve endings and dural sac by swelling, and possible exudate accumulation. The progressive circulatory disorder impairs the nutritional status of the disc and surrounding bony structures, which may lead to the formation of osteonecrosis foci.

When these complaints were identified and the diagnosis of postmanipulative spondylomyelitis was established, all patients underwent emergency osteoperforation (tunneling) of the vertebral body through the root of the arch in accordance with the following method "Method of spondylomyelitis treatment" (patent № IAP 05393 of 21.04.2017, Uzbekistan).

Osteoperforation (tunnelization) of the spine was performed in the operating room using a trocar with a diameter of 4 mm, under fluoroscopic control (Fig. 1). The trocar was inserted through the root of the arch at angles in the frontal and sagittal planes (angulation from 20 to 40°) predetermined by X-ray images under local anesthesia in such a way that it hit the centre of the lesion area. After perforation of the lamina and entry into the destruction zone, material was collected (aspiration) for bacteriological and histological examination.

An antibiotic drain was placed through the trocar before removal. After surgery, two broad-spectrum antibiotics were administered daily through both catheters until microbiological results were available (usually 7-8 days). On the 8th day the catheter was removed. Parenteral antibiotic therapy was adjusted for pathogen sensitivity. Extension of antibiotic therapy for up to 3 months (with a change of medication every 12-14 days) was indicated by the persistence of pain syndrome with increased mobility, and the persistence of laboratory markers of inflammation.



*Fig. 1. Osteoperforation kit*

1) Trocar 2 mm, 2) Trocar 4 mm, 3) Guide wire, 4) Subclavian catheter (antibiotic drain)

Thus, one-stage tunnelization of the vertebral body and intervertebral disc with transpedicular irrigator insertion provided drainage of the destruction focus, obtained a biopsy sample for histological and microbiological examination, and created conditions for local antibiotic administration.

The subject of the study was the peculiarities of the clinical and radiological picture of the disease, laboratory indices, as well as the evaluation of the effectiveness of the proposed treatment methodology. The following early indications of treatment effectiveness were considered: pain syndrome relief, reduction of sweating, improvement of general condition, increase of appetite, positive dynamics of inflammatory markers in blood tests, and reduction of bone swelling in vertebral bone according to MRI.

**RESULTS.** Histological examination of biopsy specimens in 24 patients (88%) revealed signs of inflammatory lesions. The causative agent was identified in 15 (62.87%) cases, in 9 (37.5%) of them - *Staphylococcus aureus*; in 13 cases bacteriological and histological data allowed to consider the process as aseptic.

In the main group on the first day after osteoperforation the severity of pain syndrome decreased from 6-8 to 2-3 VAS scores in all patients. In the comparison group, 5 (41.7%) patients had pain syndrome for 1.5-2 months, and its slow decrease to 3 points was observed, while 7 (58.3%) patients had no pain syndrome reduction. It should be noted that 22 (78.6%) patients in the main group were discharged

home two weeks after osteoperforation, and bed rest and antibiotic therapy were prescribed for a month.

The results of treatment were assessed clinically, taking into account improvement in quality of life, pain intensity scores according to VAS, blood tests (sed rate, CRP, leukocytosis), as well as using Oswestry questionnaire. The following results were obtained: 19 patients (67,8%) in the main group, and 2 (16,7%) in the comparison group had good results: complete regression of the pain syndrome at rest and when turning in bed, reduced feeling of fatigue when standing upright, improved clinical and laboratory indexes. According to MRI findings, bone swelling was already reduced by the third month of treatment and disappeared by 6 months; the Oswestry score averaged 22 in both groups.

Satisfactory results were observed in 4 (14.2%) patients in the main group and in 3 (25%) in the comparison group: back pain persisted and worsened after 2-3 weeks with the onset of instability - fixation with a rigid brace was prescribed. Slow decrease of complaints over 12 weeks, however, persisting pain on loading and walking for up to 7 months. The mean Oswestry score was 42 in both groups.

Clinical and radiological examination was performed after 12 months in 23 (82.1%) patients in the main group and in 5 (41.6%) in the comparison group, whose results were considered as good and satisfactory. Functional radiographs of the lumbar spine showed no pathological mobility in any patient, while MRI showed degeneration of the inflammation



zone in the absence of edema of the vertebral bodies, decreased disc height and loss of hydrophilicity of the pulposal nucleus ("black disc").

Unsatisfactory results were observed in 5 (17.8%) patients in the main group (2 patients had diabetes mellitus) and in 7 (58.3%) in the comparison group. No significant effect of the treatment was observed in the patients: the clinical and laboratory findings were consistent with the ongoing inflammatory process and, according to MRI, the retention of oedema of the bone tissue. The Oswestry score averaged 88 (Table 2).

**Table 2**

**Treatment outcomes of the compared groups**

Condition of the patients examined	Main group n=28		Comparison group n=12		$\chi^2$	P
	abs.	%	abs.	%		
<b>Good</b>	19	67,8	2	16,7%	14,34	<0,001
<b>Satisfactory</b>	4	14,2%	3	25%	3,19	>0,05
<b>Unsatisfactory</b>	5	17,8	7	58,3	5,11	<0,05

The appearance of signs of vertebral body destruction and persistence of edema according to MRI in late follow-up with increasing clinical manifestations in 4 (14.3%) patients in the main group and in 7 (58.3%) in the control group were indications for surgical treatment. Nucleotomy with ventral fusion with autografts was performed.

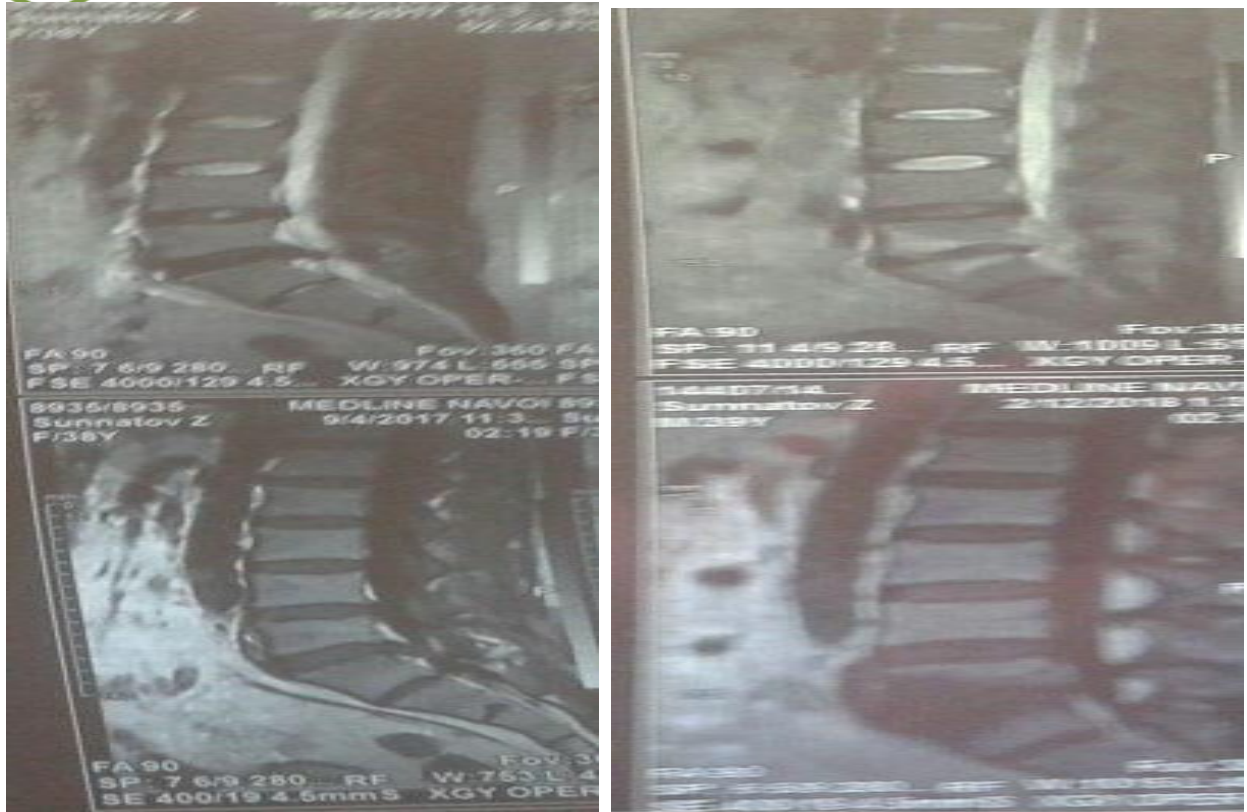
Clinical example: Patient S.Z., 40 years old, came to the clinic with complaints of severe pain in the lumbar spine, inability to turn in bed, weakness, decreased appetite. He underwent discectomy at LV-SI level from posterior access 3 months ago. After discharge from hospital his back pain worsened, his condition progressively deteriorated and he developed cramping pain on slightest movement and coughing. He was admitted to the clinic with a diagnosis of postoperative spondylodiscitis LV-SI. (Fig. 2.a.). On admission: Condition moderate in general, skin and visible mucous membranes pale, passive position in bed. Subfebrile temperature, sweating in the afternoon and especially at night. No concomitant pathology was detected.

Status Iosalis: on examination there are no visible changes in the postoperative scar area; on palpation and the slightest movement of the trunk there is pronounced pain. Pain increases when lying on the back, symptoms of radicular tension on both sides. Blood tests showed no increase in white blood cell count (WBC =  $7.6 \times 10^9$ ), sed rate = 5 mm/hour.

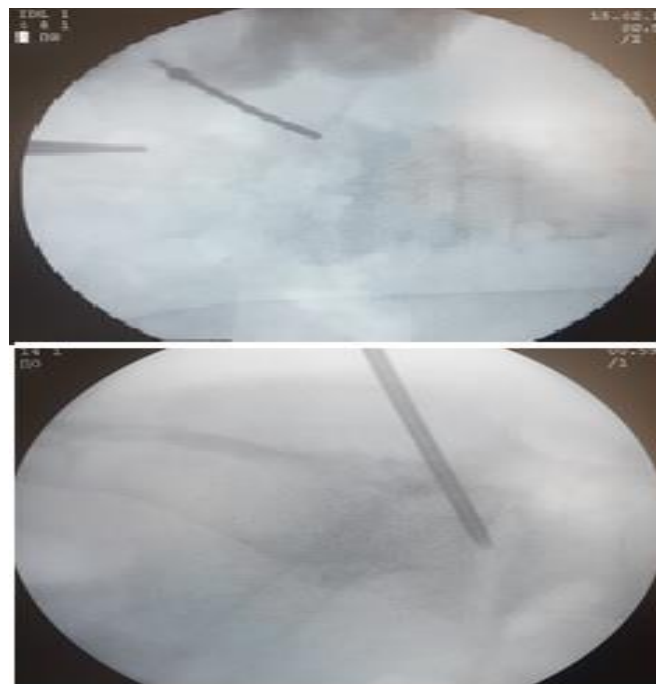
MRI in T1 and T2 modes showed bone marrow and disc swelling (Fig. 2.b).

Osteoperforation of the SI vertebra was performed under local anaesthesia on both sides, transpedicular drains were placed for sanitation and antibiotic administration (Fig. 3,4,5).


After osteoperforation, the patient's condition improved dramatically: back pain disappeared, appetite appeared, and sweating decreased. Antibacterial and anti-edema treatment was carried out (pathogen not identified).



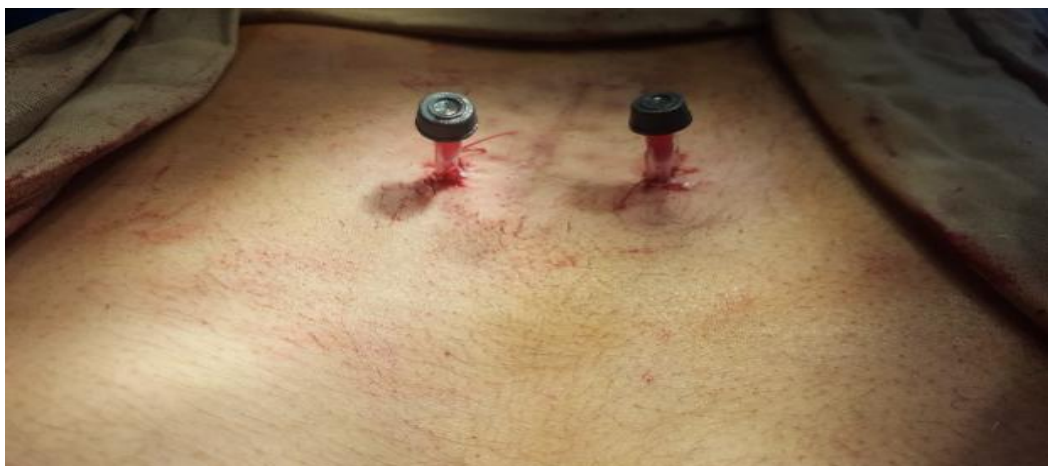*Fig. 2. Clinical example. Patient S.Z., 40 years old. Diagnosis: Postoperative spondylodiscitis LV-SI. A) MRI on admission: signs of degenerative-dystrophic lesion of the lumbosacral spine - decreased height and intestinal signal from discs LIV-V, LV-SI; herniated disc LV-SI; B) MRI 3 months after surgery: spondylodiscitis LV-SI: epidural component;*



*Fig. 3. Clinical example. Patient S.Z., 40 years old. Diagnosis: Postoperative spondylodiscitis LV-SI. Intraoperative radiographs (osteoperforation under fluoroscopic guidance)*



*Fig. 4. Clinical example. Patient S.Z., 40 years old. Diagnosis: Postoperative spondylodiscitis LV-SI. operative photos with drains in place;*



*Fig. 5. Clinical example. Patient S.Z., 40 years old. Diagnosis: Postoperative spondylodiscitis LV-SI. MRI 3 months after osteoperforation: positive dynamics in the form of reduced bone marrow swelling of the vertebral bodies, disappearance of the epidural component*

**Discussion.** The steadily increasing number of surgical interventions performed annually for degenerative-dystrophic lesions of the spine inevitably leads to an increase in the absolute number of postoperative complications accompanied by chronic pain syndrome. Clinical deterioration compared to the preoperative state is observed in 1-3% of patients. One of these complications is postoperative spondylodiscitis, the incidence of which after herniated disc removal varies considerably, reaching 3.5% with a

tendency towards a lower number of complications with minimally invasive treatment methods. The mechanical impact on the vertebral contact surfaces during herniated disc removal is accompanied by microdamage of the vertebral closing plates, and the subchondral swelling on MRI in the early postoperative period may not be a pathogenic sign of acute spondylodiscitis. In the early postoperative period, changes in the nature and severity of the pain syndrome are of the greatest diagnostic value.



At the same time, bone marrow swelling impairs local blood flow, which causes osteonecrosis in the subchondral regions of the vertebrae, from which the intervertebral disc is fed diffusely. Trepan biopsy to obtain material for histological and bacteriological examination is the leading method of diagnosing spondylodiscitis, and its value for etiological verification of the diagnosis is up to 80%. In turn, as a therapeutic procedure, biopsy of the vertebral body with a conventional trepanation needle (diameter 18 G) leads to progression of destruction due to narrow biopsy channels and inability to perform adequate drainage. Use of a trocar with a diameter of 3-4 mm allows to quickly reduce intraosseous pressure, improve blood circulation in the affected vertebra, which is accompanied by a rapid decrease in pain syndrome from 6-8 to 2-3 points according to the HACS and simultaneously drain the intervertebral disc.

**CONCLUSIONS:** Emergency osteoperforation of the vertebra and disc in combination with antibiotic therapy can reduce the severity of pain syndrome due to decompression of the lesion and reduction of edema in the adjacent vertebrae, as well as being a preventive measure of osteodestruction, which ensures good (67.8%) and satisfactory (14.2%) results in the vast majority of cases of acute postoperative spondylodiscitis. MRI changes in the form of adjacent vertebral edema in the early postoperative period are not an absolute sign of spondylodiscitis; however, the spread of edema to the entire vertebral body or to the adjacent segment, with progression of pain syndrome, is a sign of inflammatory complications in the operated segment.

#### **LIST OF REFERENCES:**

1. Bazarov A.Yu. Classification of nonspecific hematogenous osteomyelitis of the spine. Critical analysis and suggestions for application. *Traumatology and Orthopaedics of Russia*. 2019;25(1):146-155.
2. Kitov BD, Zhelyazkov HB, Petkova AS, Kehayov I, Davarsky A, Kalnev B, Kitova T. Spinal epidural abscesses as a complication of spondylodiscitis: a retrospective monocenter study // *Spine Surgery*. 2017;14(4):103-109.
3. Mushkin AY, Vishnevsky AA, Peretsmanas EO, Bazarov AY, Basankin IV Infectious lesions of the spine: draft national clinical guidelines // *Spine Surgery*: 2019. T. 16. № 4. C. 63-76..
4. Dzhuraev, A., Usmanov, Sh., Rakhmatullaev, H., & Khalimov, R. (2021). Our experience with surgical treatment of congenital elevation of the scapula in young children. *Medicine and Innovations*, 1(4), 37-44.
5. Dzhuraev, A. M., & Khalimov, R. D. (2012). Our experience in the surgical treatment of Perthes disease in children. *Postgraduate Physician*, 50(1.3), 377-383.
6. Dzhuraev, A., Usmanov, Sh., Rakhmatullaev, H., & Khalimov, R. (2021). Our experience with surgical treatment of congenital elevation of the scapula in young children. *Medicine and Innovations*, 1(4), 37-44.
7. Ismoilov, O., Kamalova, M., Anvarshed, T., & Makhmudova, S. (2021). Briefly about anatomico-physiological features of the foot and the application of some cotopic exercises to eliminate flatfoot. The SCIENTIA Collection of Scientific Papers. Retrieved from <https://ojs.ukrlogos.in.ua/index.php/scientia/article/view/9999>
8. Khodzhiyeva D.T., Pulatov S.S., Khaidarova D.K. All about haemorrhagic stroke in elderly and elderly persons (own observations) // *Science of Young People (Eruditio Juvenium)*. 2015. №3. C. 87-96.9. Djuraev, A. M., & Khalimov, R. J. (2020). New methods for surgical treatment of perthes disease in children. *International Journal of Psychosocial Rehabilitation*, 24(2), 301-307.
9. Shomurodov. K.E. Features of cytokine balance in gingival fluid at odontogenicphlegmon of maxillofacial area. // *Doctor-aspirant 2010.-42 Vol.-No.5.1.-P.187-192;*
10. Khodzhiyeva D. T., Khaydarova D. K., Khaydarov N. K. Complex evaluation of clinical and instrumental data for justification of optive treatment activities in patients with resistant forms of epilepsy. *American Journal of Research. USA*. № 11-12, 2018. C.186-193.
11. Khodzhiyeva D. T., Khaydarova D. K. Clinical and neurophysiological characteristics of post-insular cognitive disorders and issues of therapy optimization. *Central Asian Journal of Pediatrics*. Dec.2019. P 82-86
12. Sadridin Sayfullaevich Pulatov. (2022). Efficacy of ipidacrine in the recovery period of ischaemic stroke. *World Bulletin of Public Health*, 7, 28-32.
13. Tukhtarov B.E., Comparative assessment of the biological value of average daily diets in



professional athletes of Uzbekistan. *Gig. Sanit.*, 2010, 2, 65–67.

14. A. Karshiboyev, C. Meliboyev Tunnelization in lumbar spondylodiscitis. // *Медицинский Альянс*; 2017: 3: 84-89.
- 2) 16. Akiyama T, Chikuda H, Yasunaga H, Horiguchi H, Fushimi K, Saita K. Incidence and risk factors for mortality of vertebral osteomyelitis: a retrospective analysis using the Japanese diagnosis procedure combination database. *BMJ Open*. 2013;3:e002412. DOI: 10.1136/bmjopen-2012-002412.
- 3) 17. Ilkhomovna, K. M., Eriyigitovich, I. S., & Kadyrovich, K. N. (2020). Morphological Features Of Microvascular Tissue Of The Brain At Hemorrhagic Stroke. *The American Journal of Medical Sciences and Pharmaceutical Research*, 2(10), 53-59. <https://doi.org/10.37547/TAJMSPR/Volume02Issue10-08>